



The Evaluation and Management of Drooling

Sarah Rodriguez, MD

Byron Bailey, MD

January 2003

Drooling

- **Salivary incontinence or the spillage of saliva over the lower lip**
- **Reflects inefficient, uncoordinated swallowing and poorly synchronized lip closure**
- **Also known as ptyalism**
- **Sialorrhea: an increase in salivary flow which can lead to drooling**

Functions of Saliva

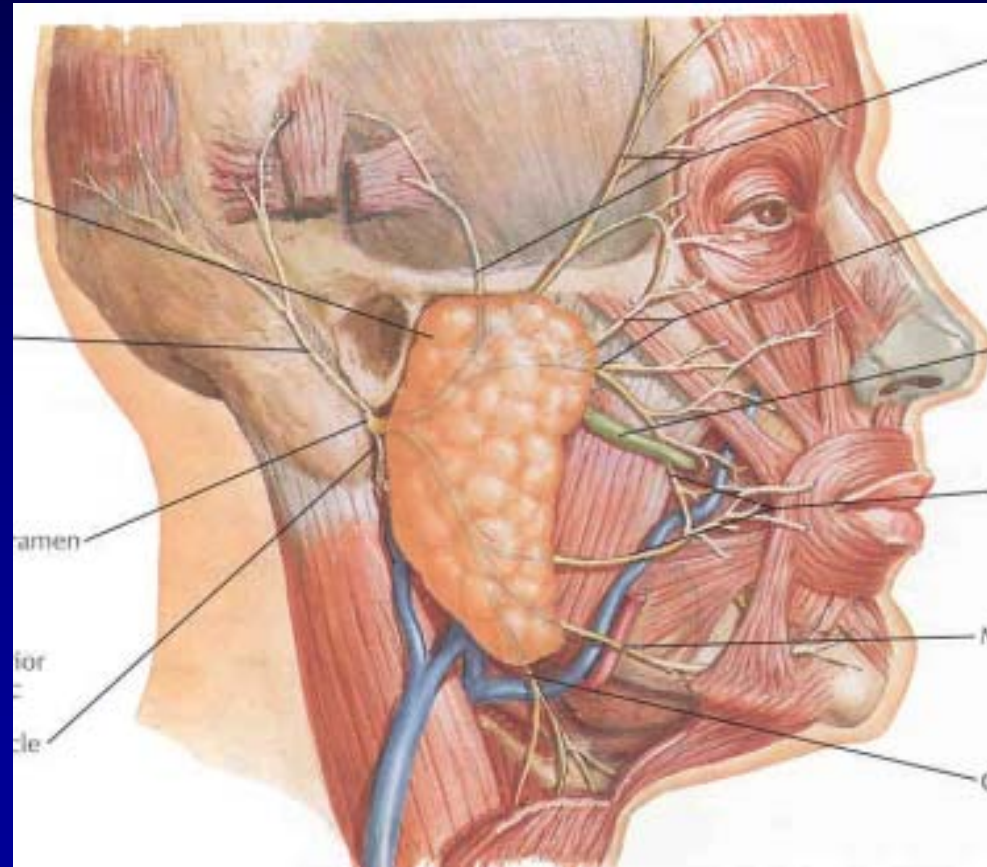
- **Moistening of food bolus**
- **Prevention of dental caries**
- **Protection of mucosa from desiccation**
- **Medium for lysozyme, secretory IgA, salivary peroxidase**
- **Digestion**

Salivary Glands

- **Parotid gland: 25% of daily salivary flow; serous**
- **Submandibular gland: 70% of daily salivary flow; serous and mucinous**
- **Sublingual glands: 5% of daily salivary flow; mucinous**
- **During stimulated flow, the relative contribution of the parotid glands and the submandibular glands are reversed**
- **Controlled by the autonomic nervous system, primarily the parasympathetic nervous system**

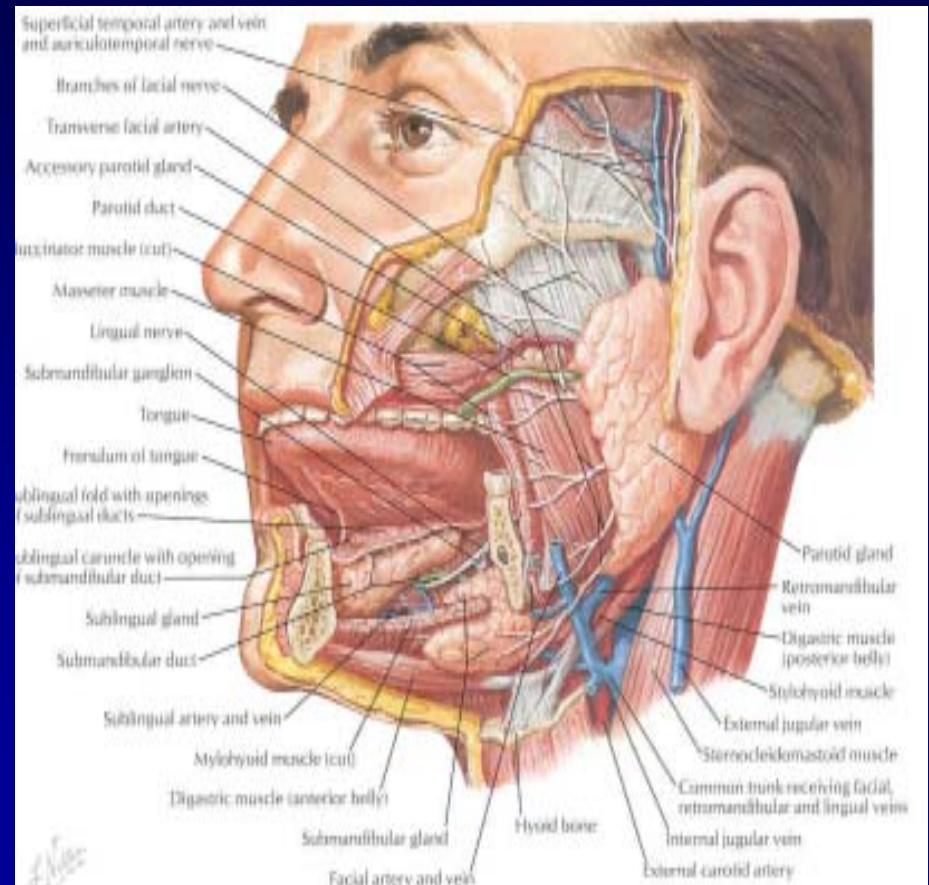
Parotid Gland

- Preganglionic PS fibers originate in inferior salivary nucleus in medulla
- CN9->petrosal ganglion->lesser superficial petrosal nerve->otic ganglion->auriculotemporal nerve



Submandibular and Sublingual Glands

- Preganglionic PS fibers originate superior salivary nucleus in medulla
- Nervus intermedius->CN7->chorda tympani->lingual nerve->submandibular ganglion



Etiology of Drooling

- **Acute: epiglottitis, neoplasm, peritonsillar abscess**
- **Chronic: neurologic, medication effects, indirect**

Chronic Drooling

- **Neurologic: cerebral palsy, strokes, amyotrophic lateral sclerosis, Parkinson's disease, congenital suprabulbar palsy**
- **Medications: tranquilizers, anticonvulsants, anticholinesterases**
- **Indirect: nasal obstruction, malocclusion, tongue size, head posture, sitting position, emotional state**

History

- **Estimated quantity of saliva, use of bibs, clothing changes**
- **Nasal obstruction secondary to adenoid hypertrophy, rhinitis, sinusitis, nasal deformities**
- **Extent of underlying neurologic disease**
- **Hearing loss**

Physical Exam

- **Head posture**
- **Sores on lips or chin**
- **Dental problems**
- **Tongue control**
- **Swallowing control**
- **Consider: audiogram, barium swallow, modified barium swallow**

Treatment Options

- **Speech therapy**
- **Behavioral therapy**
- **Radiation therapy**
- **Medications**
- **Botulinum Toxin**
- **Surgery**

Speech Therapy

- **Goals: improve jaw stability and closure, increase tongue mobility and strength, improve lip closure, decrease nasal regurgitation**
- **Usually disappointing results unless started in infancy**
- **Severely retarded patients get little benefit**

Behavior Therapy

- **Incorporates cuing, positive and negative reinforcement, overcorrection**
- **Can be fairly successful in patients with adequate intelligence**
- **Labor intensive**
- **Regression common**

Medications

- **Glycopyrrolate: 70-90% response rates; 30-35% will discontinue medication due to side effects (excessive dry mouth, constipation, urinary retention, decreased sweating, irritability)**
- **Trihexyphenidyl: efficacy and side effects similar to glycopyrrolate; may be useful in dystonic CP due to tone reduction**
- **Scopolamine patch can also be used and has the advantage of only needing to be changed every three days**

Radiation Therapy

- **Has been used to control drooling in patients with amyotrophic lateral sclerosis with success**
- **Decrease drooling with few side effects in this terminally ill population**

Botulinum Toxin

- **Several recent small series report success with intraglandular injection of botulinum toxin**
- **Studies mostly use adult patients however Jongerius reports three children with cerebral palsy had botox injected into both submandibular glands with significant decrease in drooling and no adverse effects**

Surgical Therapies

- **Duct rerouting procedures**
- **Excision of salivary glands**
- **Ligation of salivary gland ducts**
- **Combinations of all the above**
- **Laser photocoagulation of parotid gland ducts**

Parotid Duct Relocation

- **Wilkie was first to propose surgical treatment for drooling and performed parotid duct relocation which produced unsatisfactory results**
- **Wilkie and Brodie then added submandibular gland excision with success; however 35% complication rate**

Duct Ligation

- **Parotid duct ligation technically easy with few complications; however associated with 50% re-fistulization rate**
- **Submandibular duct ligation not advised as saliva constituents more apt to form stones and route of duct is “uphill”**

Submandibular Duct Relocation

- **Crysdale performed submandibular duct relocation on 226 patients with good results however complicated by ranula and lateral neck cysts**
- **Addition of sublingual gland excision for next 296 patients yielded good results with no ranula formation**

Submandibular Duct Relocation

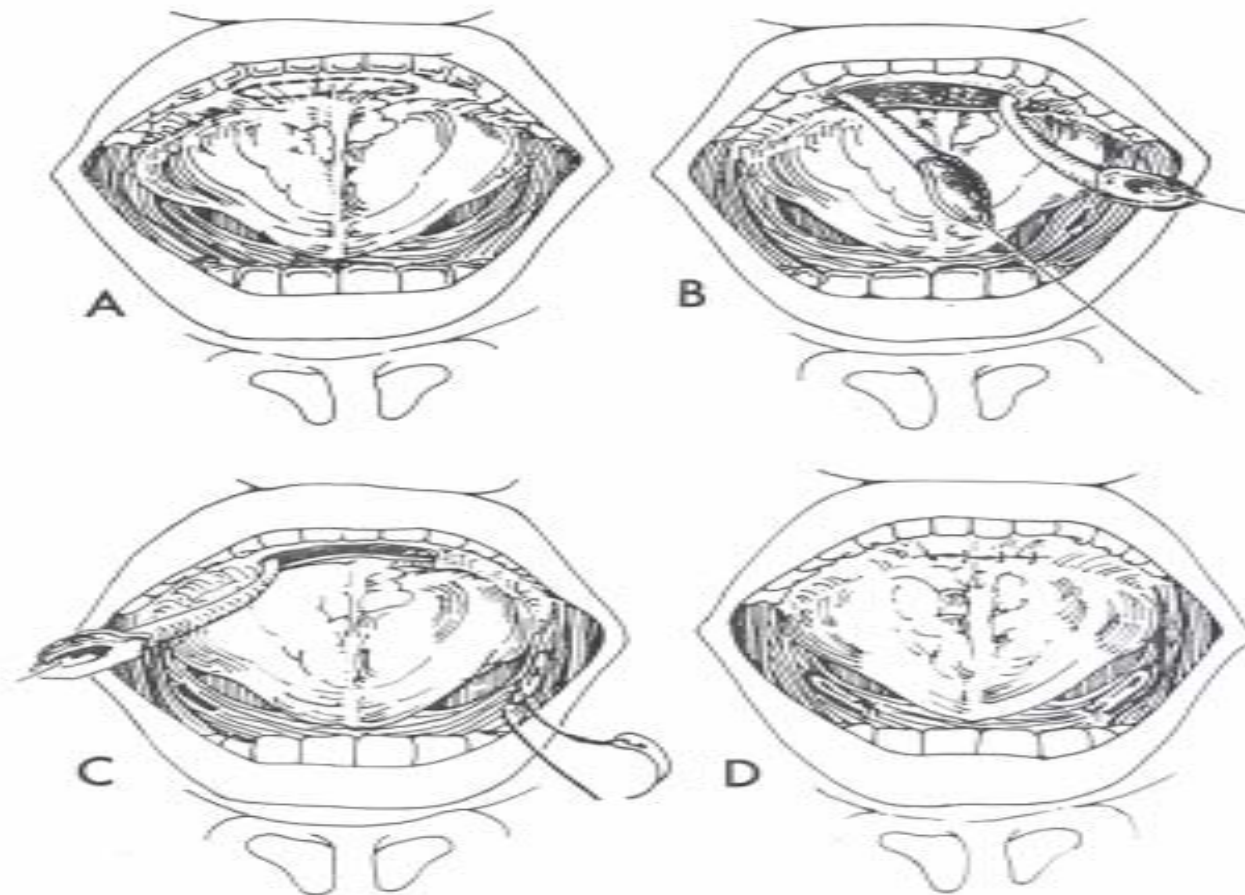


Fig. 7. Bilateral submandibular duct relocation. A. Elliptical area of mucosa centered about the sublingual papillae. It will be divided in the midline to provide islands of mucosa about each submandibular duct orifice. B. Both ducts mobilized back to region of lingual nerve. Note traction sutures through each island of mucosa avoiding each submandibular duct. C. Right submandibular duct being sutured into right tonsillar fossa after being pulled through submucosal tunnel. D. Both ducts sutured in place and anterior incision closed.

Transtympanic Neurectomy

- **80% success rate**
- **Lift tympanomeatal flap, locate and divide chorda tympani and branches of the tympanic nerves**
- **Few complications**

Intraductal Laser Photocoagulation

- **Recent study by Chang reports results on 48 patients with cerebral palsy who underwent intraductal laser photocoagulation of bilateral parotid ducts**
- **47 patients showed improvement in drooling, only one patient showed no change**
- **Few complications**

Conclusion

- **Noninvasive modalities should be attempted first**
- **A trial of medication is warranted if noninvasive methods fail**
- **Surgery is a final option for those patients with severe drooling problems not adequately addressed by noninvasive means or medication**