





Parapharyngeal Space Tumors

Gordon Shields, M.D.

Byron Bailey, M.D.

October 9, 2002

- 
-
- Account for 0.5% of all head and neck neoplasms
 - Benign: 80% Malignant 20%
 - Surgical excision is the primary treatment

- 
-
- Anatomy
 - Pathology
 - Clinical evaluation
 - Imaging with CT, MRI, angiography
 - Surgical treatment
 - Nonsurgical options

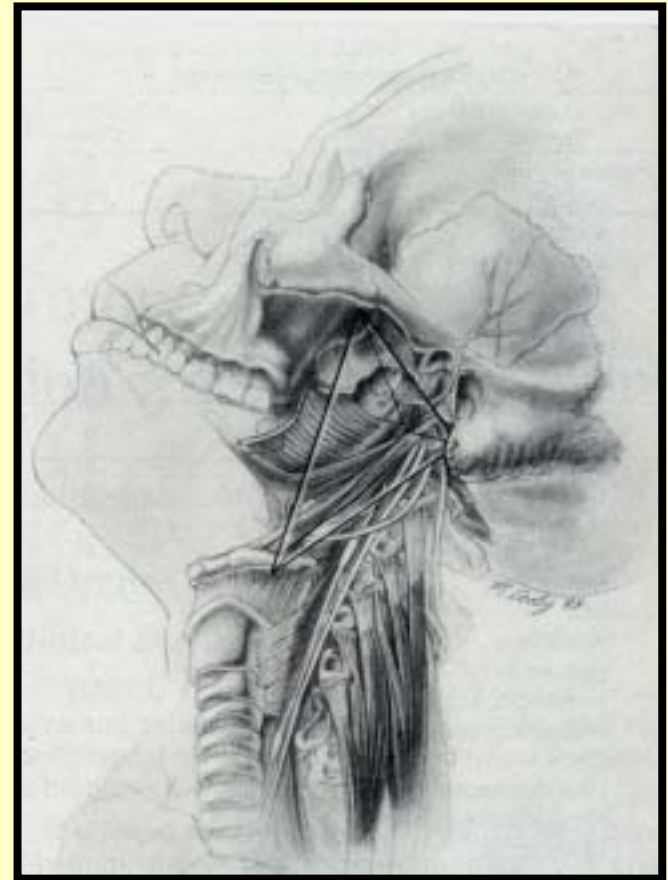

Key Points to Remember:

- Differential of prestyloid vs. retrostyloid
- Most common neoplasms
- Imaging clues to help with diagnosis

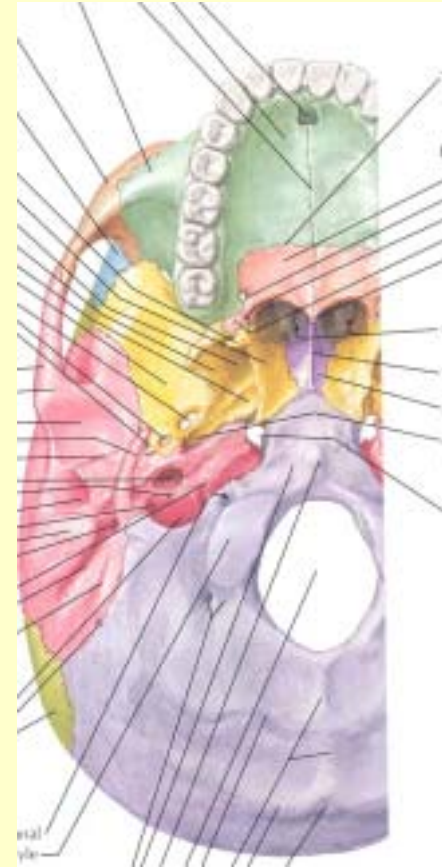Anatomy


- Inverted pyramid with floor at skull base, tip at hyoid
- Potential space




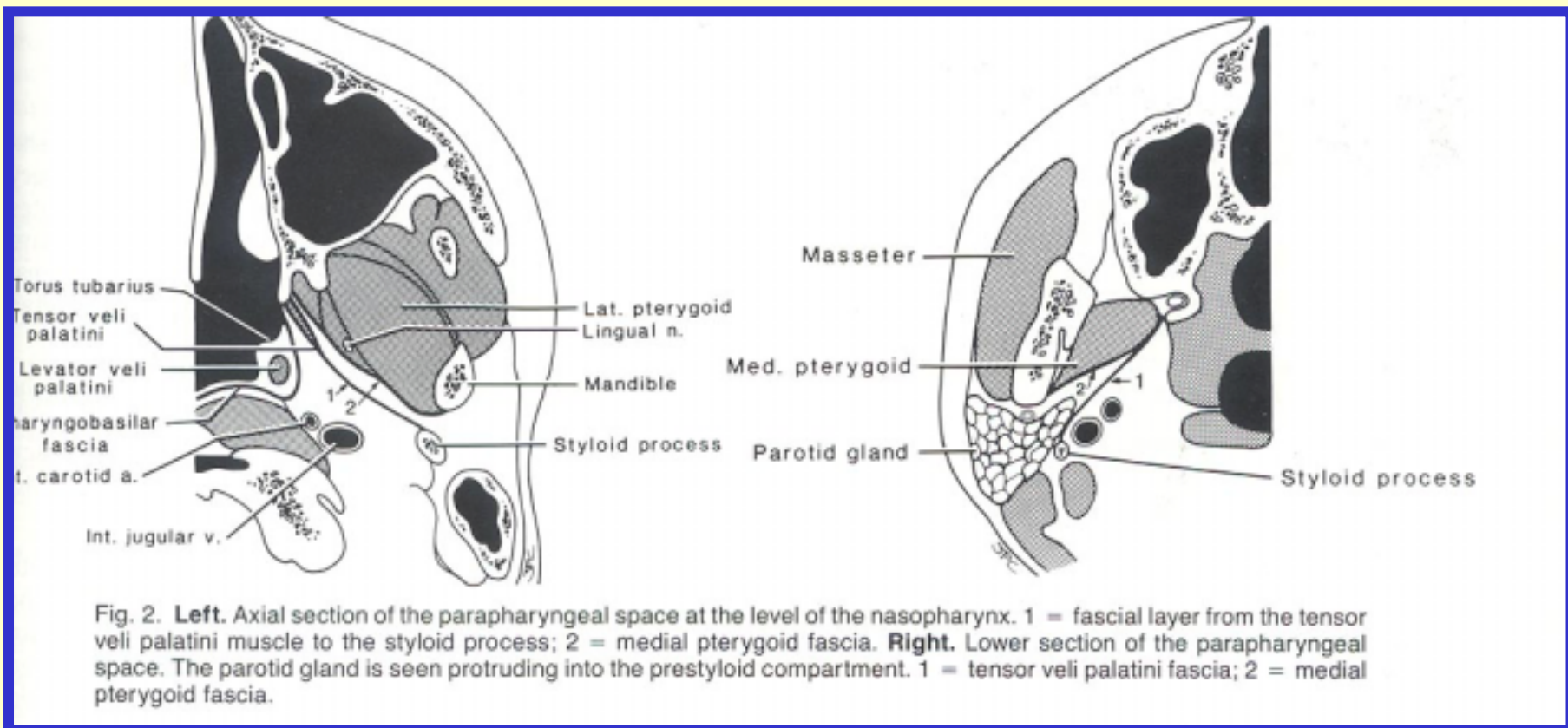
Superior Boundary

- Small portion of temporal and sphenoid bones



- 
-
- Inferior: junction of posterior belly of the digastric and greater cornu of hyoid
 - Medially: buccopharyngeal fascia over superior constrictors
 - Laterally: fascia overlying medial pterygoid muscle, ramus of mandible, and fascia overlying retromandibular parotid

- 
-
- Anterior: pterygomandibular raphe
 - Posterior: dorsal layer of fascia of the carotid sheath
 - Internal carotid artery, jugular vein, CN IX-XII, sympathetic chain all course through this space





Prestyloid vs Retrostyloid

- Key anatomical division of PPS
- Tensor-vascular styloid fascia divides into prestyloid and retrostyloid spaces
- Anterolateral prestyloid/posteriormedial retrostyloid
- Used to make differential diagnosis based on imaging

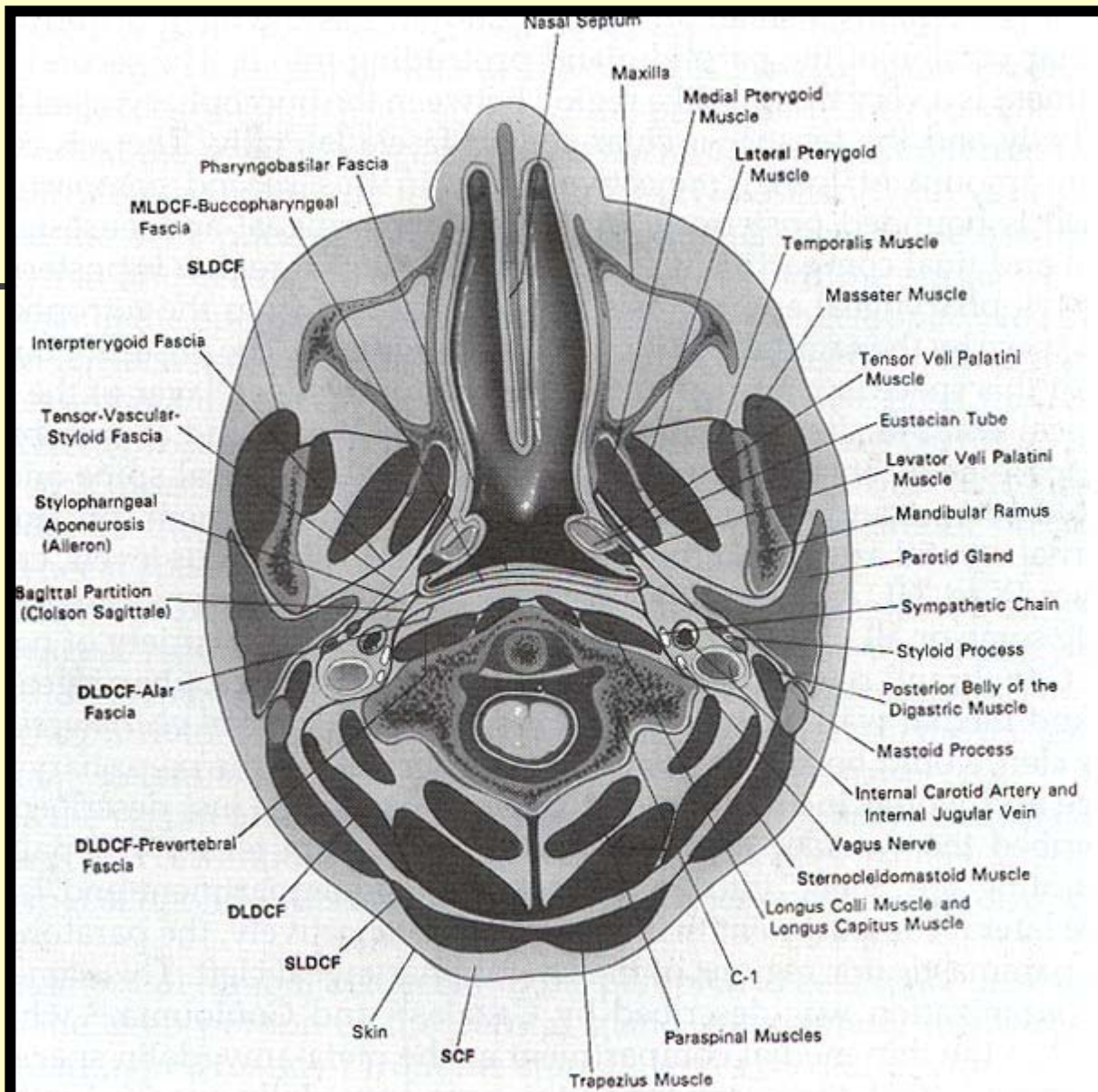


Figure 1. Axial drawing of the fascia in and about the parapharyngeal spaces.



Prestyloid compartment

- Fat
- Retromandibular parotid
- lymphnodes



Retrostyloid compartment

- Internal carotid artery
- Jugular vein
- Sympathetic chain
- Cranial nerves IX-XII
- Lymphnodes



Stylomandibular Tunnel

- Posterior ramus of the mandible
- Stylomandibular ligament
- Skull base
- Path for deep parotid tumors

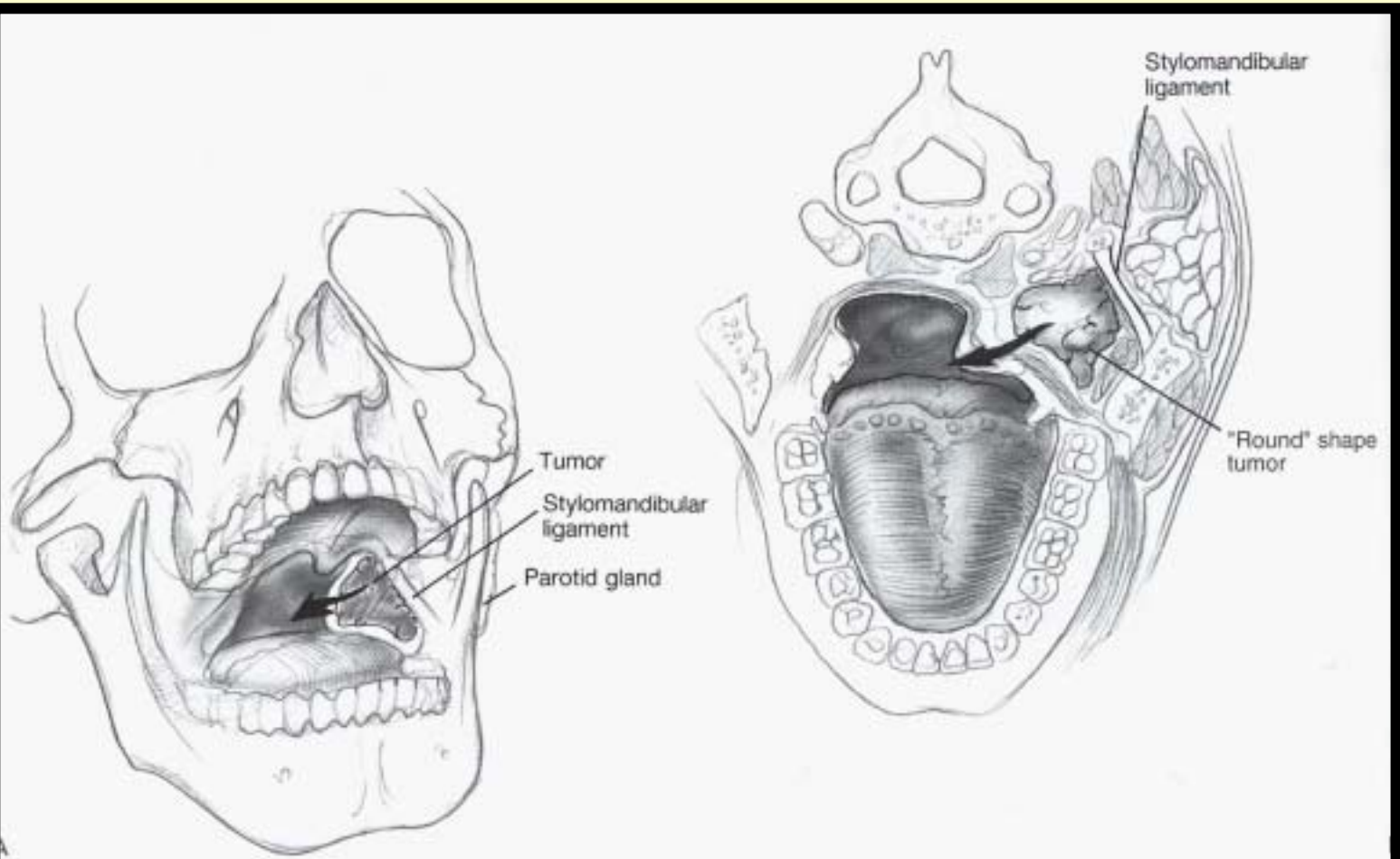


FIGURE 107.14. Round tumor involving the parapharyngeal space. Three fourths (A) and axial (B) anteroposterior view.

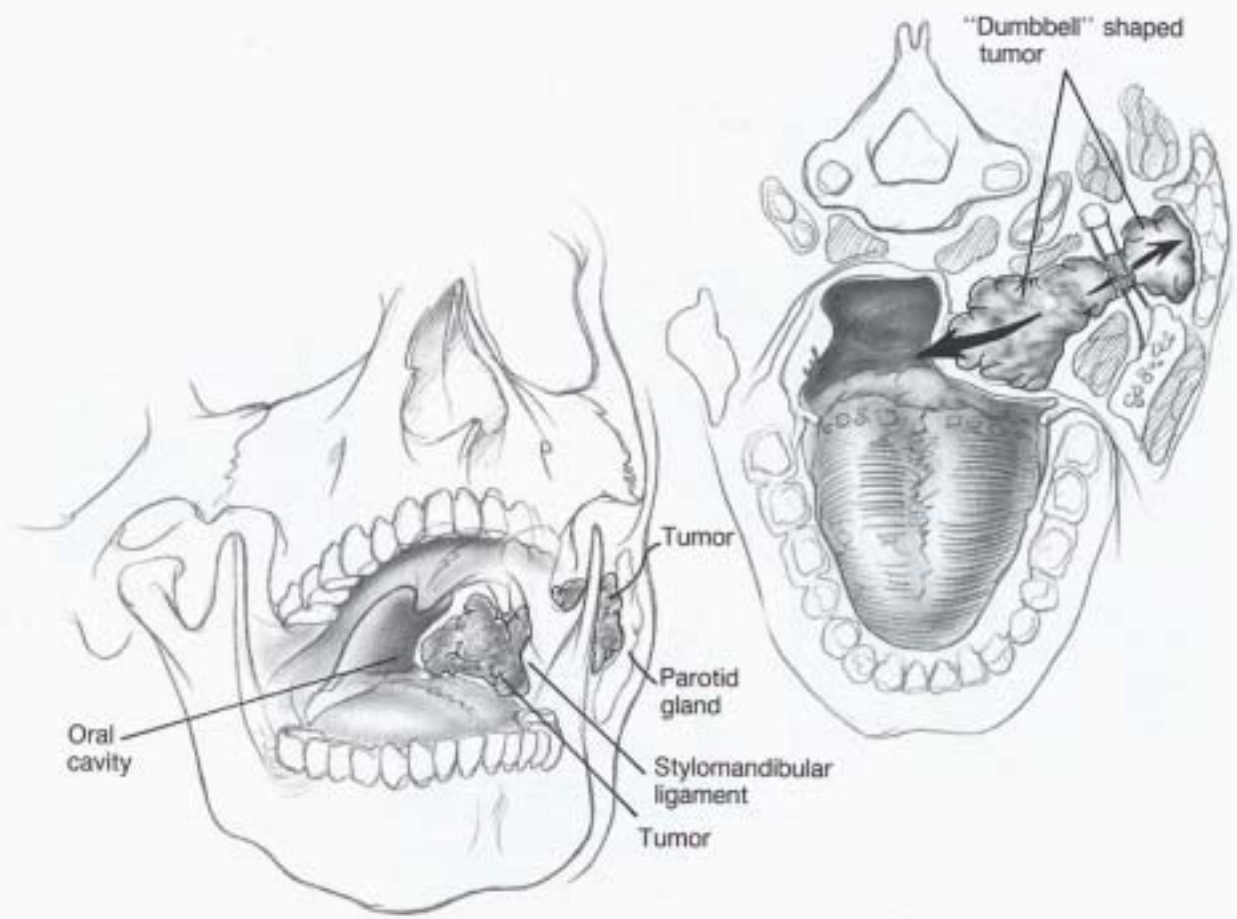
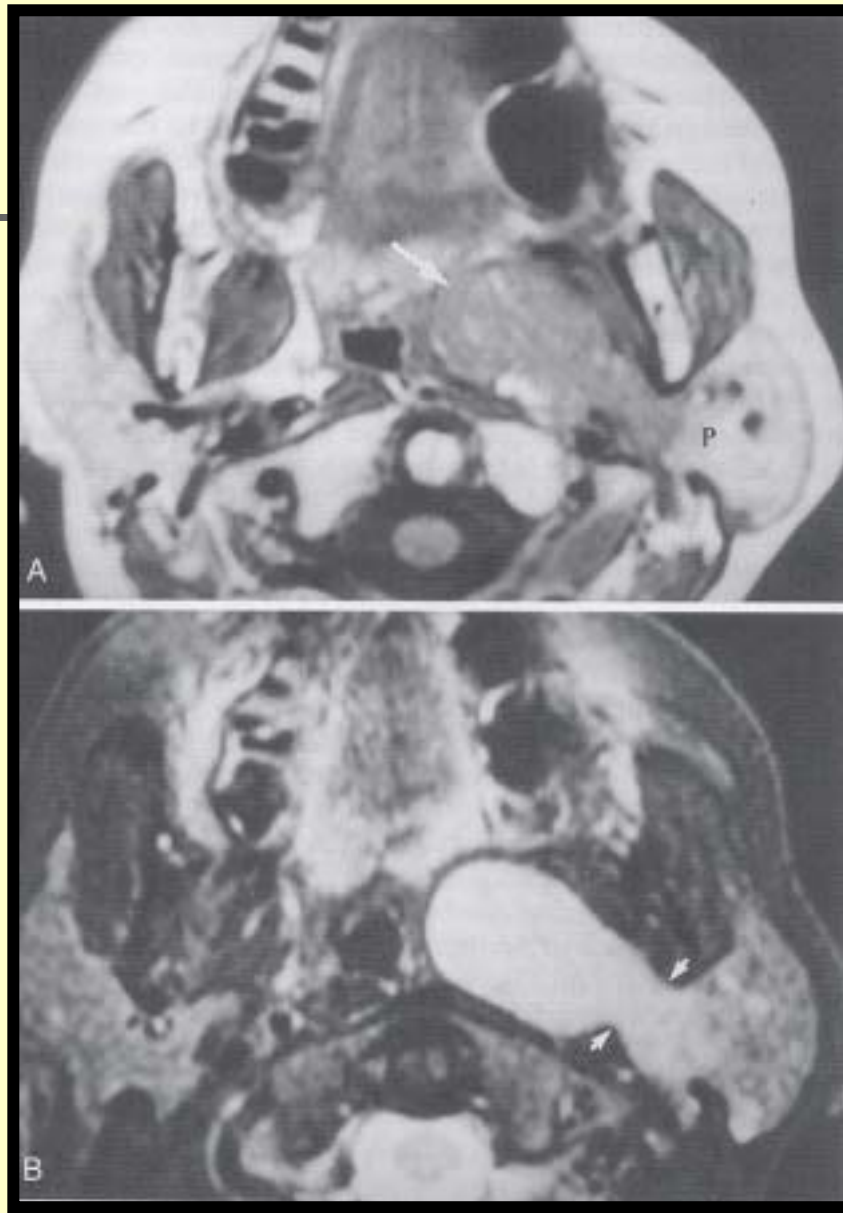



FIGURE 107.15. Dumbbell tumor involving the parapharyngeal space. Three fourths (A) and axial (B) anteroposterior view.





Pathology

- Benign 80%
- Malignant 20%
- Direct extension, metastasis, primary tumors



Direct Extension

- Mandible
- Maxilla
- Nasopharynx
- Neck
- Oral cavity
- Oropharynx
- Temporal bone



Metastasis

- Follicular thyroid cancer
- Papillary thyroid cancer
- Medullary thyroid cancer
- Osteogenic sarcoma
- Squamous cell carcinoma



Primary Tumors

- Three categories:
- Salivary gland tumors
- Neurogenic tumors
- Miscellaneous tumors



Salivary Gland Tumors

- Most common PPS neoplasms: 40-50%
- Prestyloid masses
- Pleomorphic adenoma 80-90%
- Mucoepidermoid most common malignant
- Less than 5% parotid tumors involve the PPS



Salivary Gland Tumors

- Located in prestyloid space
- From deep lobe of parotid or minor salivary glands
- On CT or MRI a fat plane between the parotid and a prestyloid mass indicates minor salivary gland origin
- Displace the internal carotid posteriorly



Neurogenic Tumors: 17-25%

- Schwannoma or neurilemmioma
- Paraganglioma
- Neurofibroma




Schwannoma

- Most common neurogenic neoplasm
- Vagus, sympathetic chain most common
- Benign and slow growing
- Generally don't affect nerve of origin
- Less than 1% malignant
- Displace internal carotid anteriorly



Paraganglioma


- Second most common
- Arise from nodose ganglion of vagus, extend superiorly from carotid body, extend inferiorly from jugular bulb
- Bilateral 10%, familial 30%
- Part of MEN IIA or IIB (medullary thyroid carcinoma, pheochromocytoma, parathyroid hyperplasia- with or without mucosal neuromas)

- 
-
- Secrete catecholamines 1-3%
 - Malignant 10%
 - Glomus vagale displace carotid anteriorly
 - Carotid body tumors splay internal and external carotid – “lyre” sign



Neurofibromas

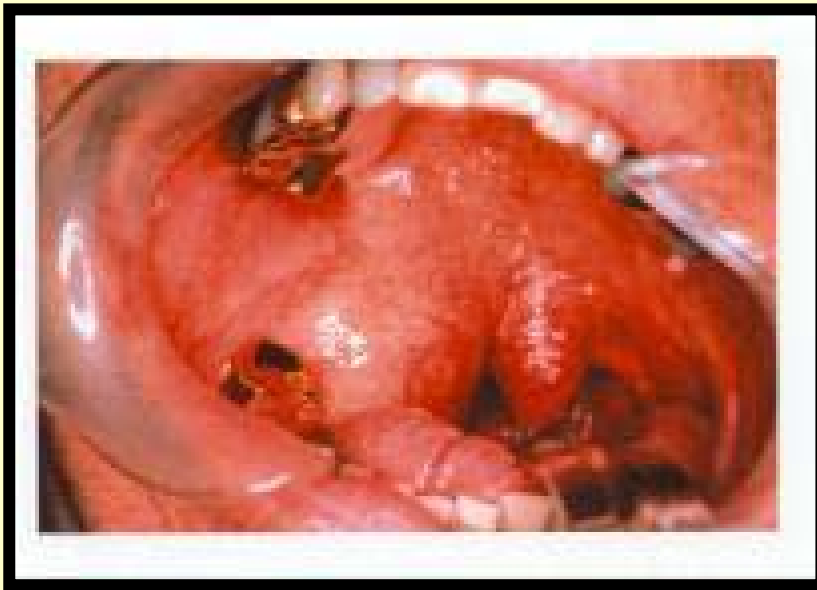
- 3rd most common neurogenic tumor
- From Schwann cells and fibroblasts
- Unencapsulated (involve nerve)
- Multiple
- Part of Neurofibromatosis type I




Miscellaneous Tumors

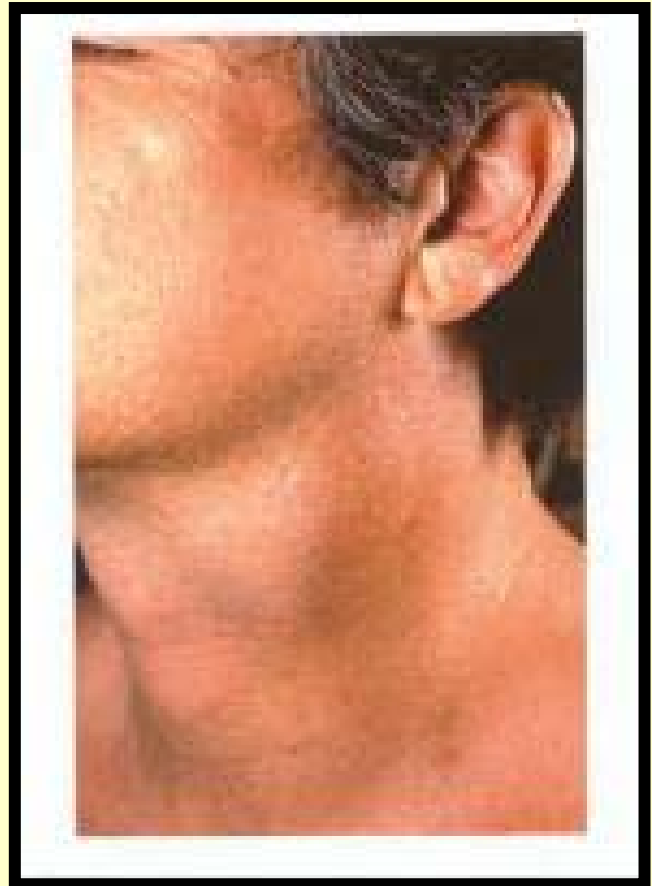
- Wide variety of tumors
- 20% of total PPS tumors
- Lymphoma, hemangioma, teratoma, lipoma, branchial cleft cyst, arteriovenous malformation, internal carotid artery aneurysm


Clinical evaluation




- Deep neck space so must reach 2-3 cm before palpable
- Neck mass 53%
- Oropharyngeal bulge 51%

- 
-
- Dysphagia, dyspnea, unilateral effusion, pulsatile tinnitus, bruit, thrill, otalgia, airway obstruction, hoarseness globus, TVC palsy, Horner's, dysarthria, hypertension, flushing



- 
-
- Complete head and neck exam
 - Bimanual palpation
 - Classically, paragangliomas mobile anterior-posterior but not up and down
 - FNA after imaging

- 
-
- If paraganglioma is suspected need to check 24 hour urine for catecholamines: VMA, metanephrines, etc
 - Metaiodinated benzylguanidine (MIBG)



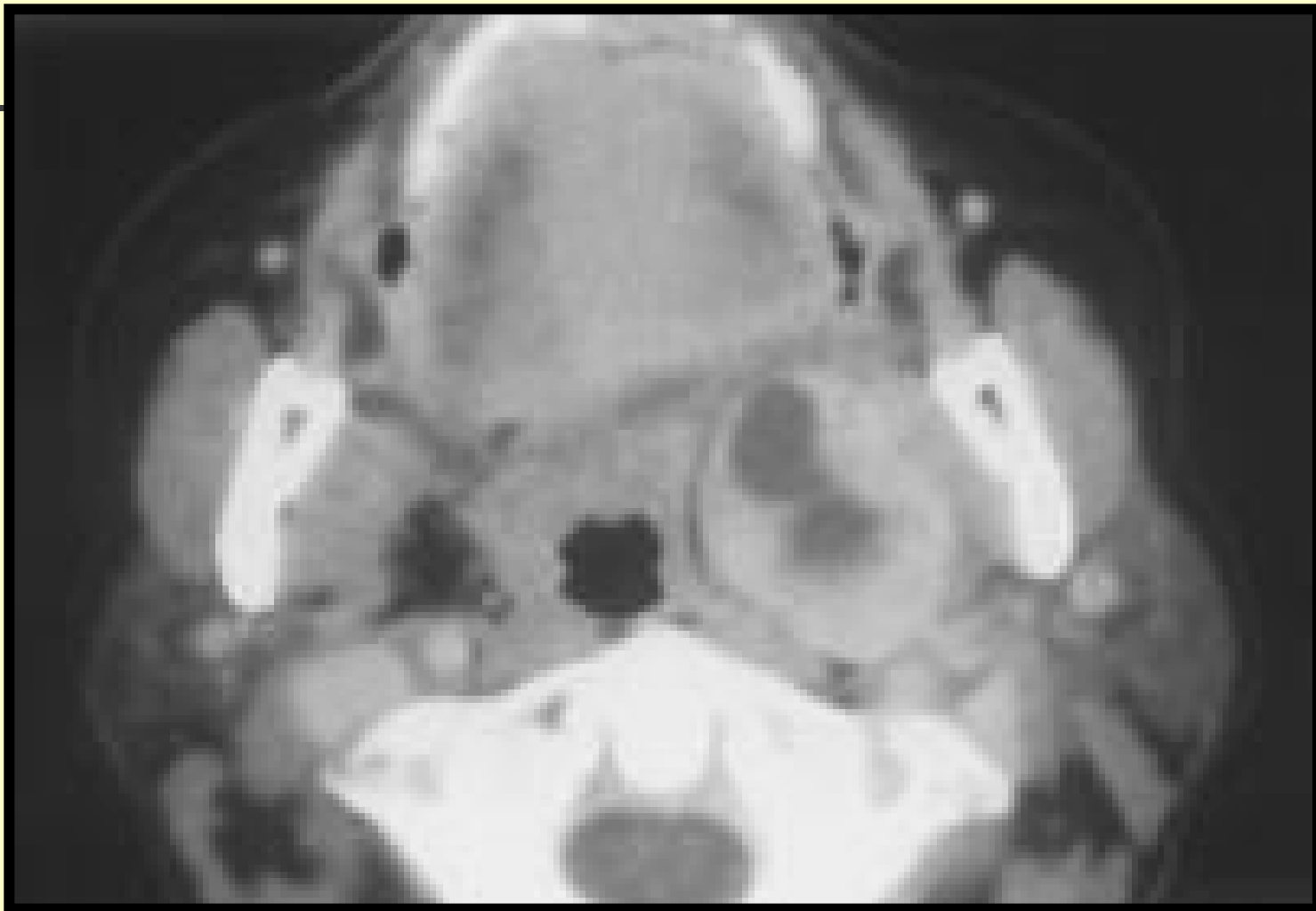
Imaging

- CT
- MRI/MRA
- angiography



CT

- Locates tumor to prestyloid vs retrostyloid
- Fat plane between mass and parotid
- Displacement of carotid
- Enhancement of lesion
- Bone erosion due to malignancy
- Limited soft tissue detail





MRI

- Most useful study
- Relationship of mass and carotid more easily seen than with CT
- Characteristic appearances of tumor types on MRI allows preoperative Dx in 90-95% of patients



Pleomorphic adenoma

- Low signal intensity on T1
- High signal intensity on T2
- Displace carotid posteriorly

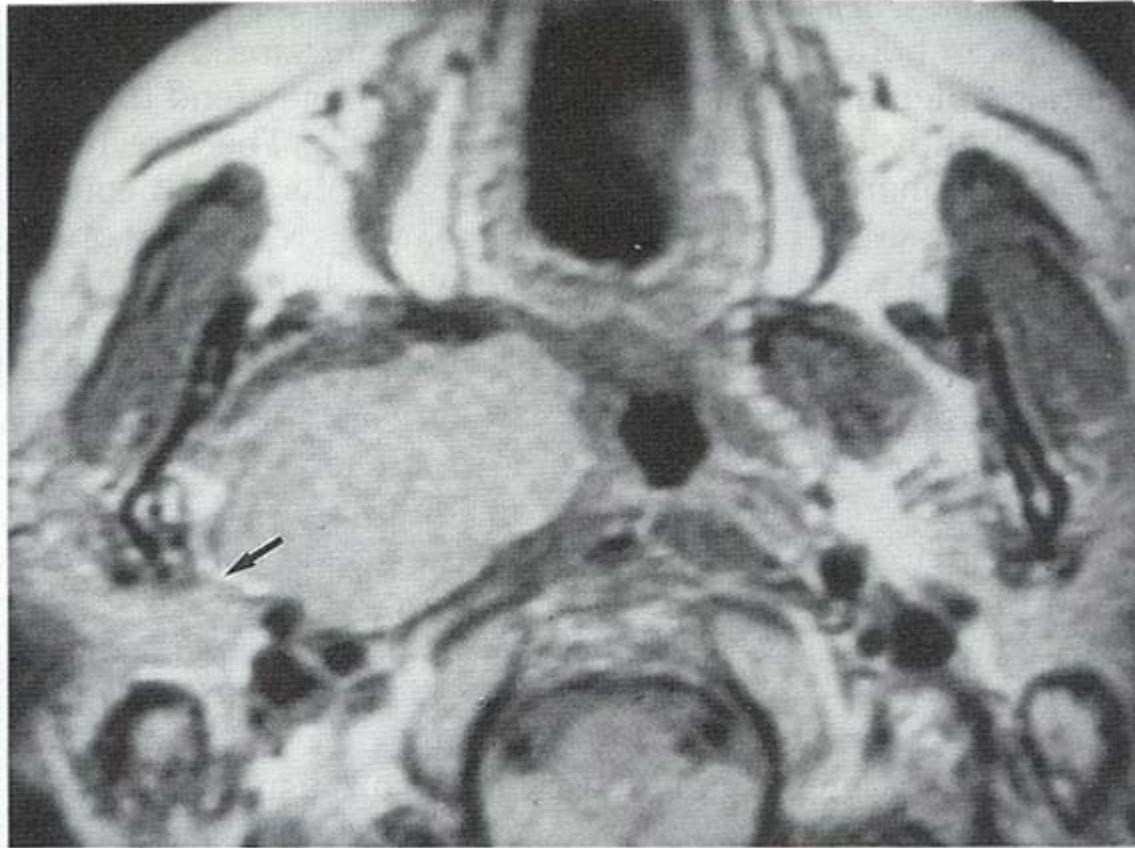


Figure 3. Axial proton density (2500/20) MR scan shows a right parapharyngeal space mass with an intermediate signal intensity. The lesion has a slightly lobulated contour and fat is present between the posterolateral margin of the mass and the parotid gland (*arrow*). This extraparotid benign mixed tumor is also anterior to the internal carotid artery.



Schwannoma

- High signal intensity on T2
- Displace carotid anteriorly

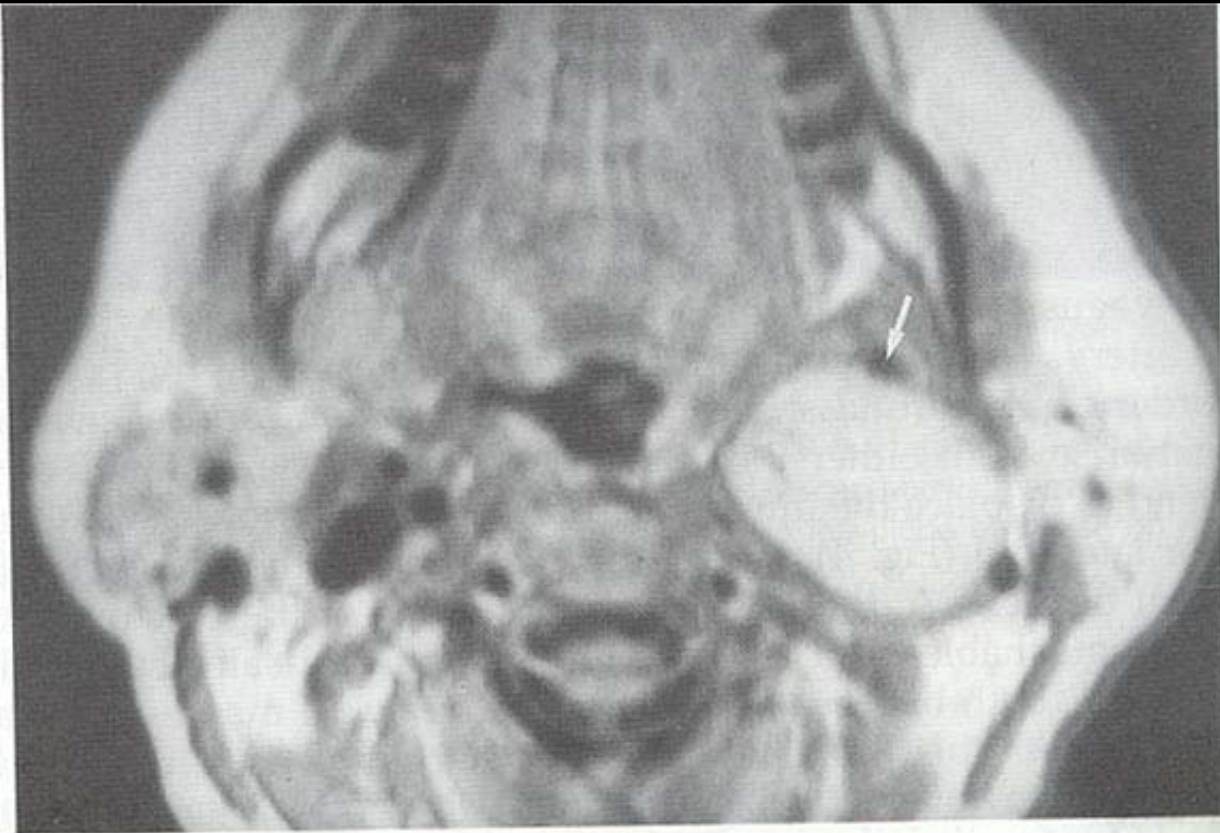

Figure 4. Axial proton density (2400/22) MR scan shows a right parapharyngeal space mass that has displaced the internal carotid artery anteriorly (*arrow*). This vagal schwannoma had a fat plane between it and the parotid gland.



Paraganglioma

- Numerous flow voids
- “Salt and pepper” appearance
- Displace carotid anteriorly

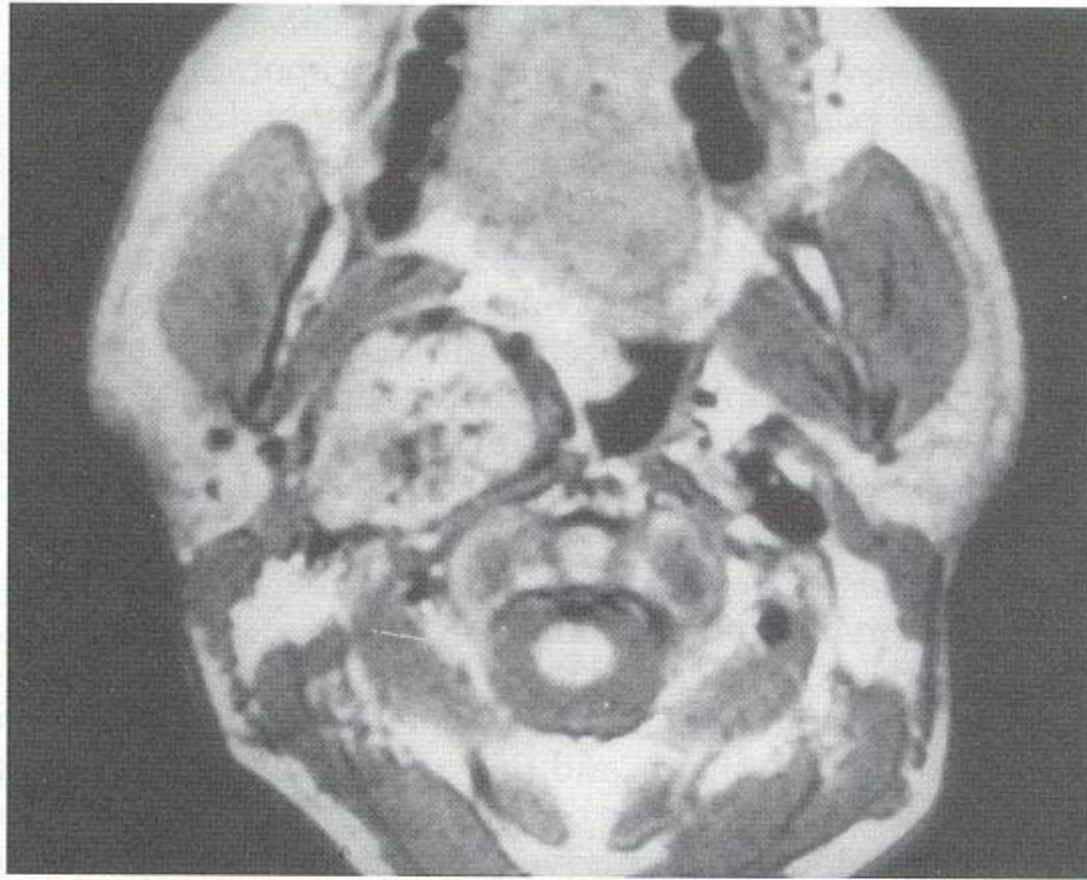


Figure 6. Axial T1-weighted (700/20) MR scan shows a right extraparotid parapharyngeal space mass that has displaced the internal carotid artery anteriorly. This glomus vagale tumor has numerous flow voids within it.

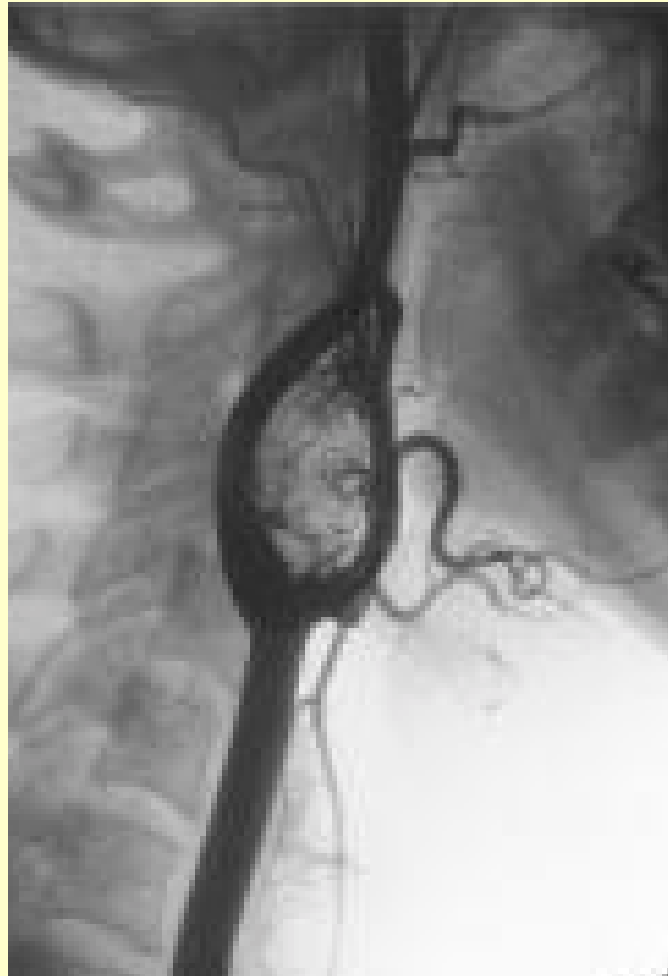


Angiography

- Used to be all enhancing lesions
- Gold standard for relationship to great vessels
- Differentiate neurogenic and vascular
- Remember “lyre” sign
- Balloon occlusion test if possible sacrifice



"Lyre" sign



- 
-
- Tumor embolization can be performed on paragangliomas 24 hours prior to procedure
 - May cause fibrosis making dissection difficult



Surgical approaches

- Transoral
- Cervical with or without mandibulotomy
- Cervical-parotid
- Transparotid
- Cervical-transpharyngeal “swing”
- Infratemporal fossa
- Transcervical-transmastoid

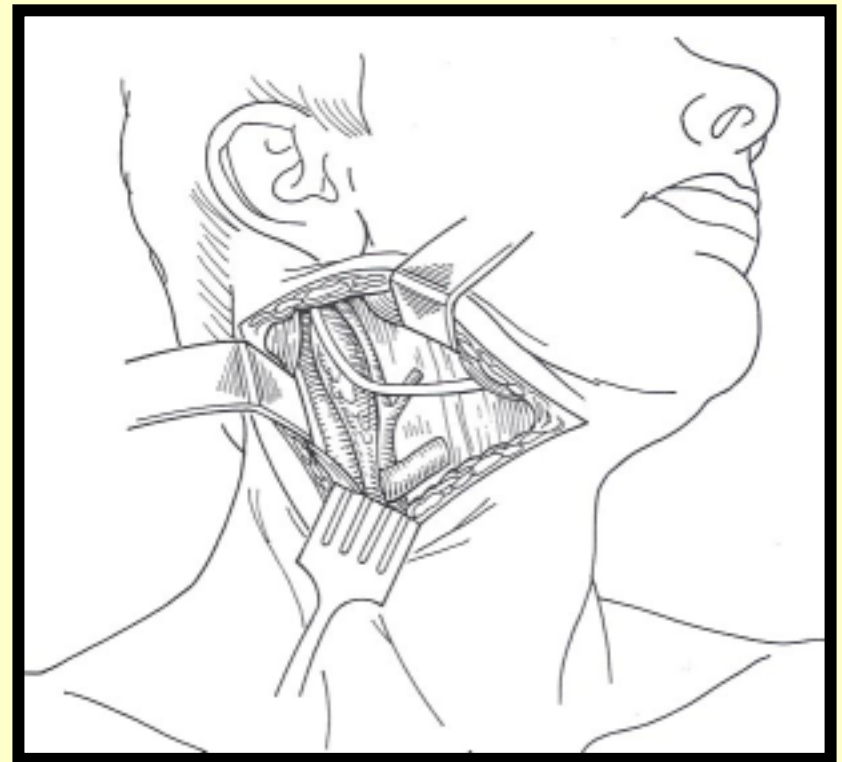

Transoral

- Has been used for small, benign tumors
- Very limited exposure
- Increased risk of tumor spillage, neurovascular injury

Cervical

- With or without mandibulotomy
- Transverse incision at level of hyoid
- Submandibular gland displace or removed
- Increase exposure by releasing digastric, stylohyoid, styloglossus from hyoid, cut stylomandibular ligament, mandibulotomy





Cervical-parotid

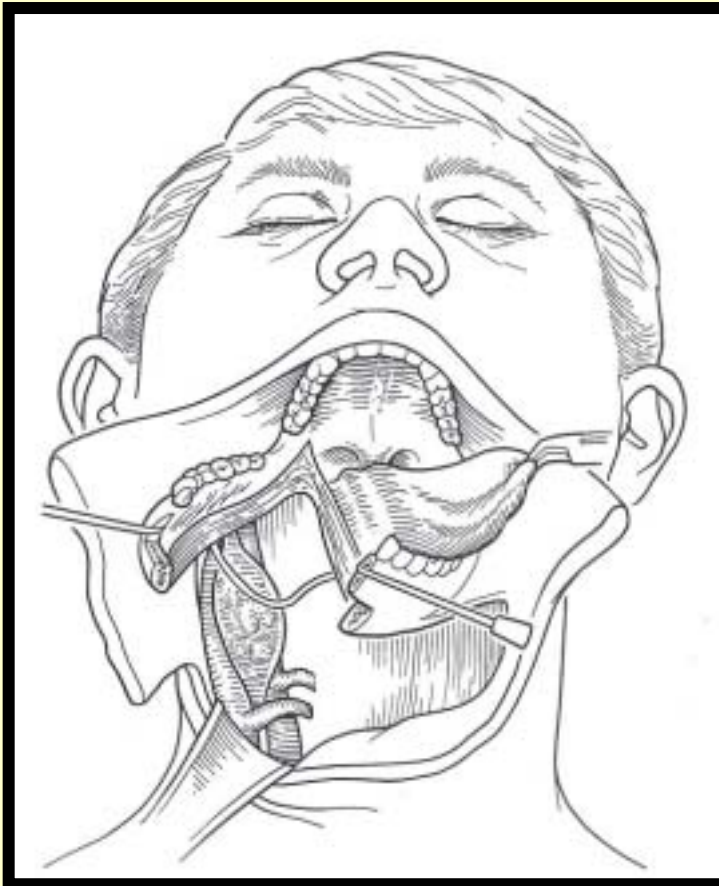
- Extend cervical incision up in front of ear
- Allows identification facial nerve
- Divide posterior belly digastric
- Divide stylomandibular ligament, styloglossus, stylohyoid close to styloid process
- Can use mandibulotomy



Transparotid

- For deep lobe parotid tumors
- Superficial parotidectomy
- Facial nerve retracted
- Dissect around mandible
- May use mandibulotomy

Cervical-transpharyngeal



- “mandibular swing”
- Large or highly vascular tumors
- Mandibulotomy anteriorly, incise along floor of mouth to anterior tonsillar pillar
- Need a tracheotomy

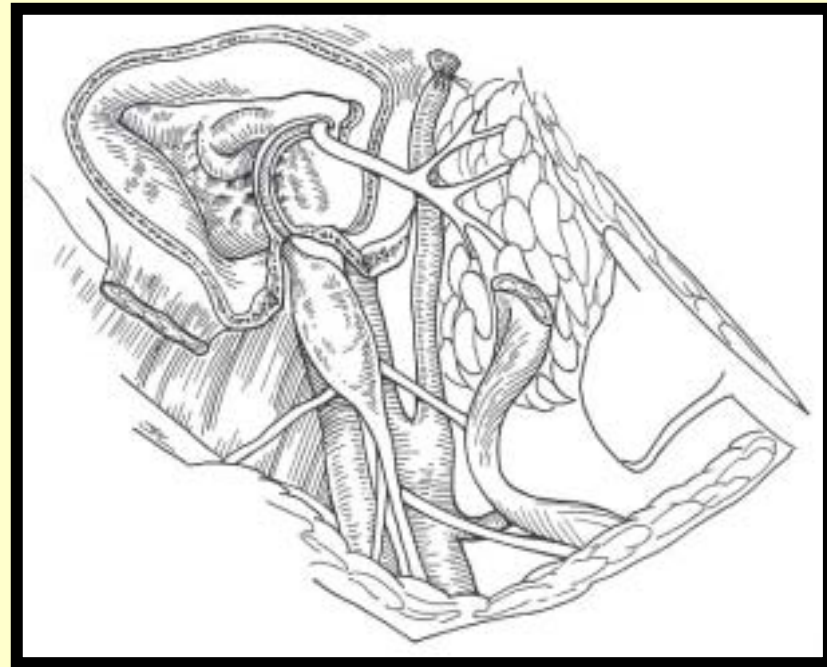


Infratemporal fossa

- Preauricular lateral infratemporal fossa approach
- Skull base or infratemporal fossa involvement
- Can combine with frontotemporal craniotomy

Transcervical-transmastoid

- Cervical incision carried postauricularly
- Mastoidectomy
- Remove mastoid tip exposing jugular fossa
- Facial nerve may need to be dissected from Fallopiian canal





Nonsurgical Management

- Poor surgical candidates, failed balloon occlusion, elderly, unresectable lesions, would require sacrifice of multiple cranial nerves
- Observation
- Radiation



Observation

- Paraganliomas grow 1.0-1.5 mm per year
- Benign
- Mortality less than 10% per year for untreated



Radiation

- Not curable
- Used for local control
- Some shrink, mostly stops growth
- Local control 90-100% reported



Key things to remember:

- Prestyloid vs. retrostyloid
- Pleomorphic most common prestyloid
- Neurogenic tumors are retrostyloid
- “Dumbbell” tumor
- “salt and pepper” appearance
- Most are benign
- Surgery is mainstay of therapy