

# Benign Thyroid Disease

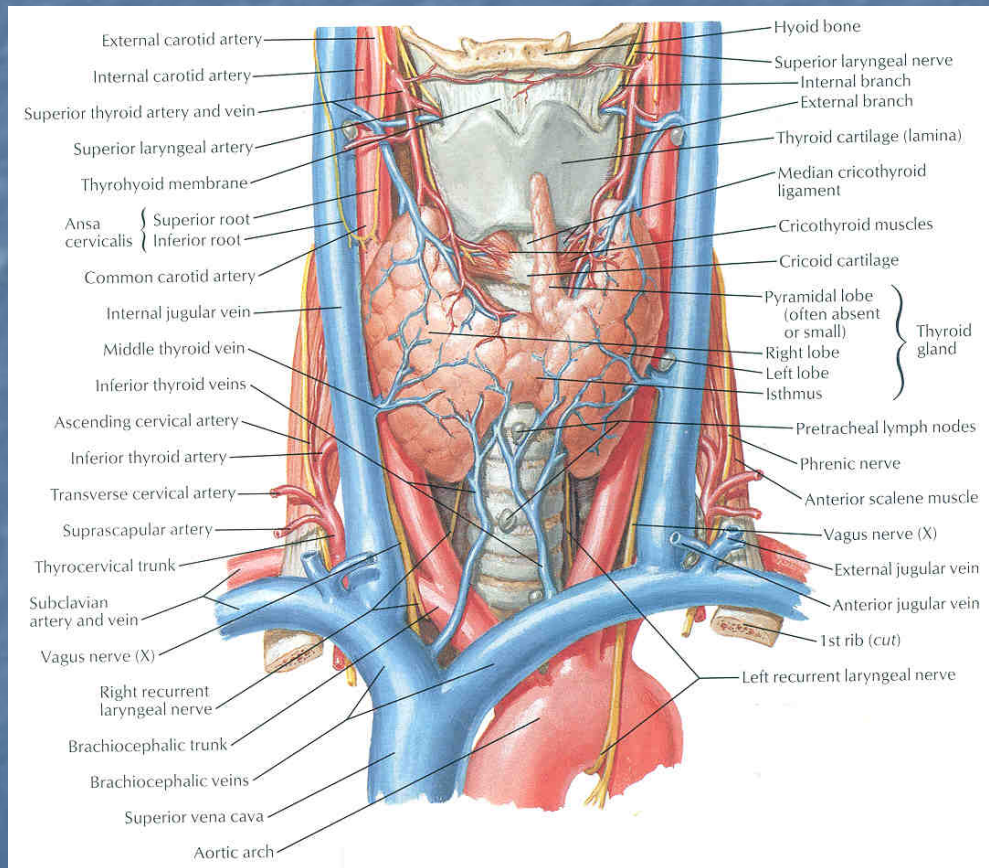
Sarah Rodriguez, MD

Francis Quinn, MD

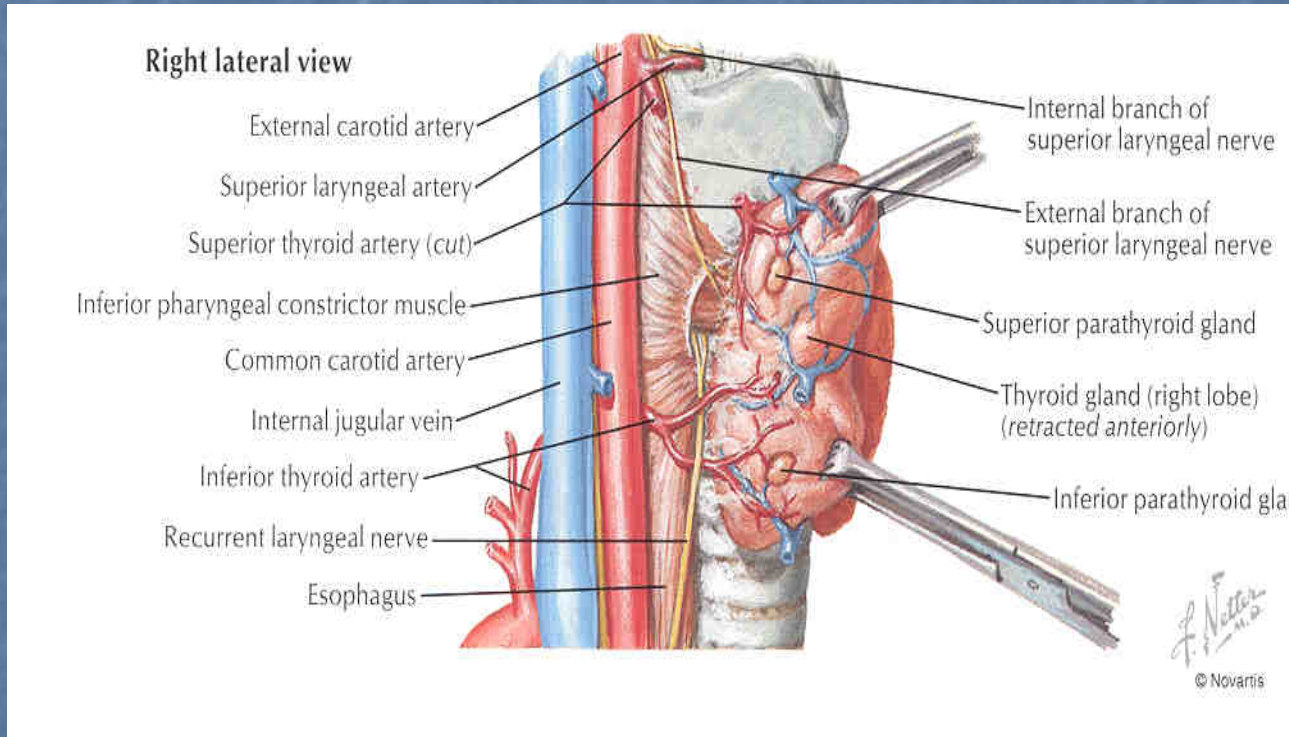
# Benign Thyroid Disease

- Benign Nontoxic Conditions
  - Diffuse and Nodular Goiter
- Benign Toxic Conditions
  - Toxic Multinodular Goiter
  - Graves' Disease
  - Toxic Adenoma
- Inflammatory Conditions
  - Chronic (Hashimoto's) Thyroiditis
  - Subacute (De Quervain's) Thyroiditis
  - Riedel's Thyroiditis

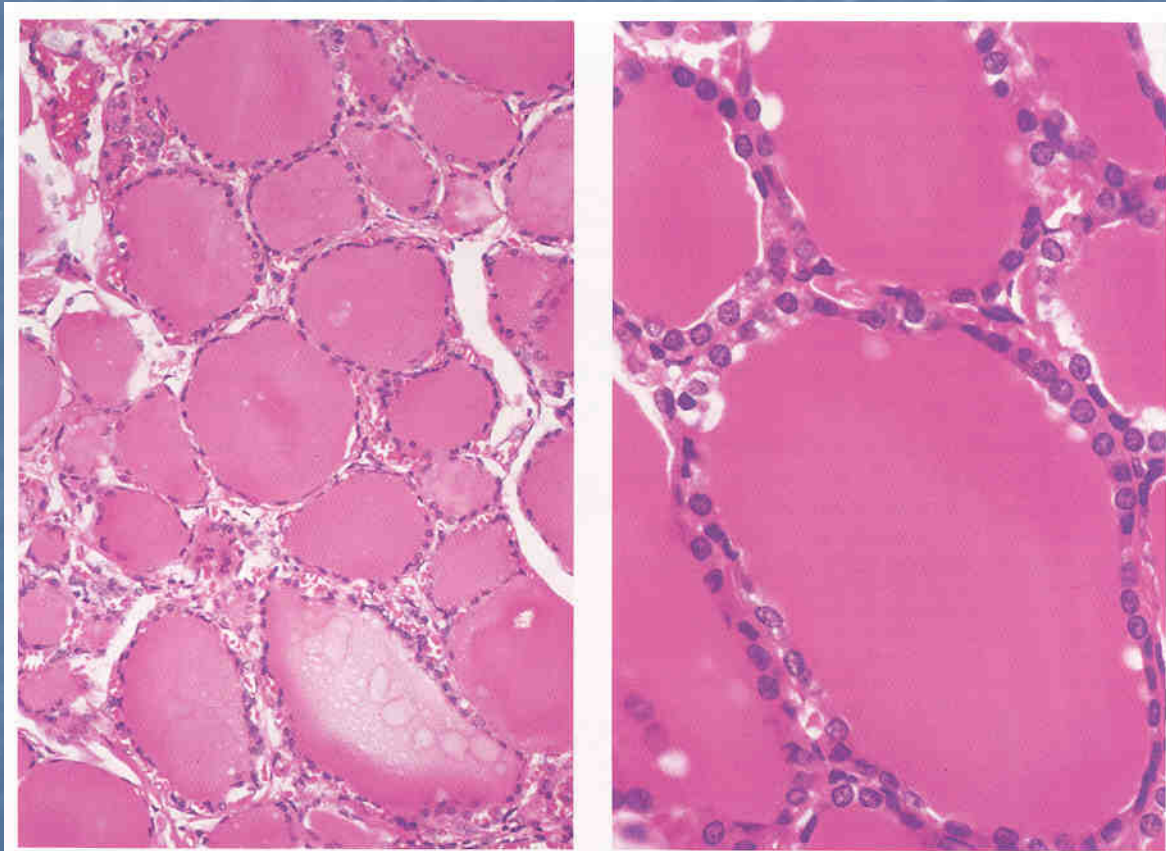
# Anatomy



# Anatomy

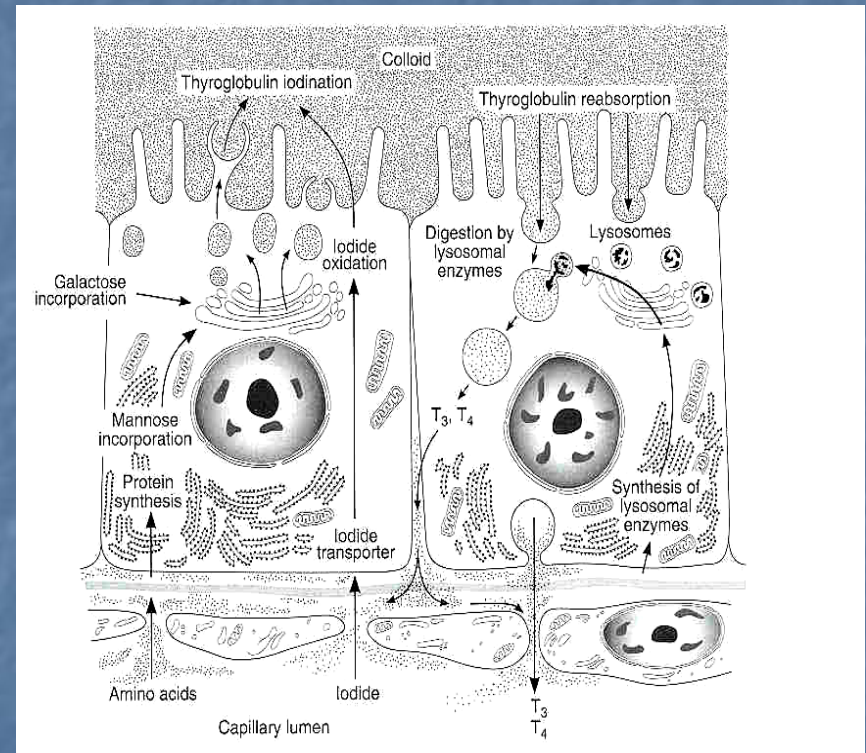


# Histology

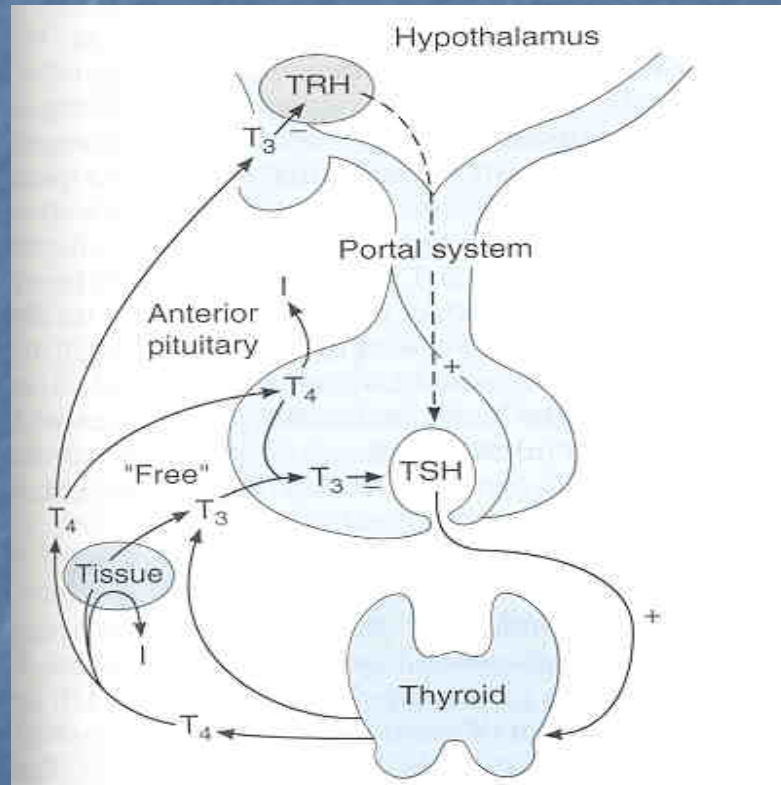


# Thyroid Hormone Synthesis

- 1. Iodide trapping
- 2. Oxidation of iodide and iodination of thyroglobulin
- 3. Coupling of iodotyrosine molecules within thyroglobulin (formation of T3 and T4)
- 4. Proteolysis of thyroglobulin
- 5. Deiodination of iodotyrosines
- 6. Intrathyroidal deiodination of T4 to T3



# Hypothalamic Pituitary Axis



# Effects of Thyroid Hormone

- Fetal brain and skeletal maturation
- Increase in basal metabolic rate
- Inotropic and chronotropic effects on heart
- Increases sensitivity to catecholamines
- Stimulates gut motility
- Increase bone turnover
- Increase in serum glucose, decrease in serum cholesterol

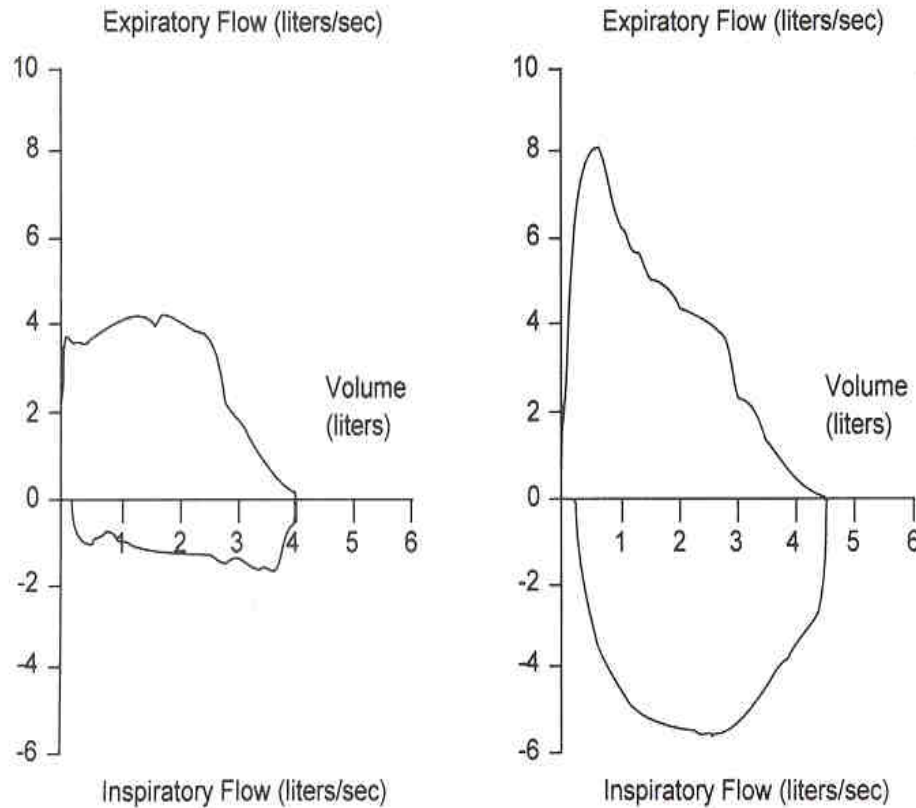
# Goitrogenesis

- Iodine deficiency results in hypothyroidism
- Increasing TSH causes hypertrophy of thyroid (diffuse nontoxic goiter)
- Follicles may become autonomous; certain follicles will have greater intrinsic growth and functional capability (multinodular goiter)
- Follicles continue to grow and function despite decreasing TSH (toxic multinodular goiter)
- Sporadic vs. endemic goiter

# Presentation

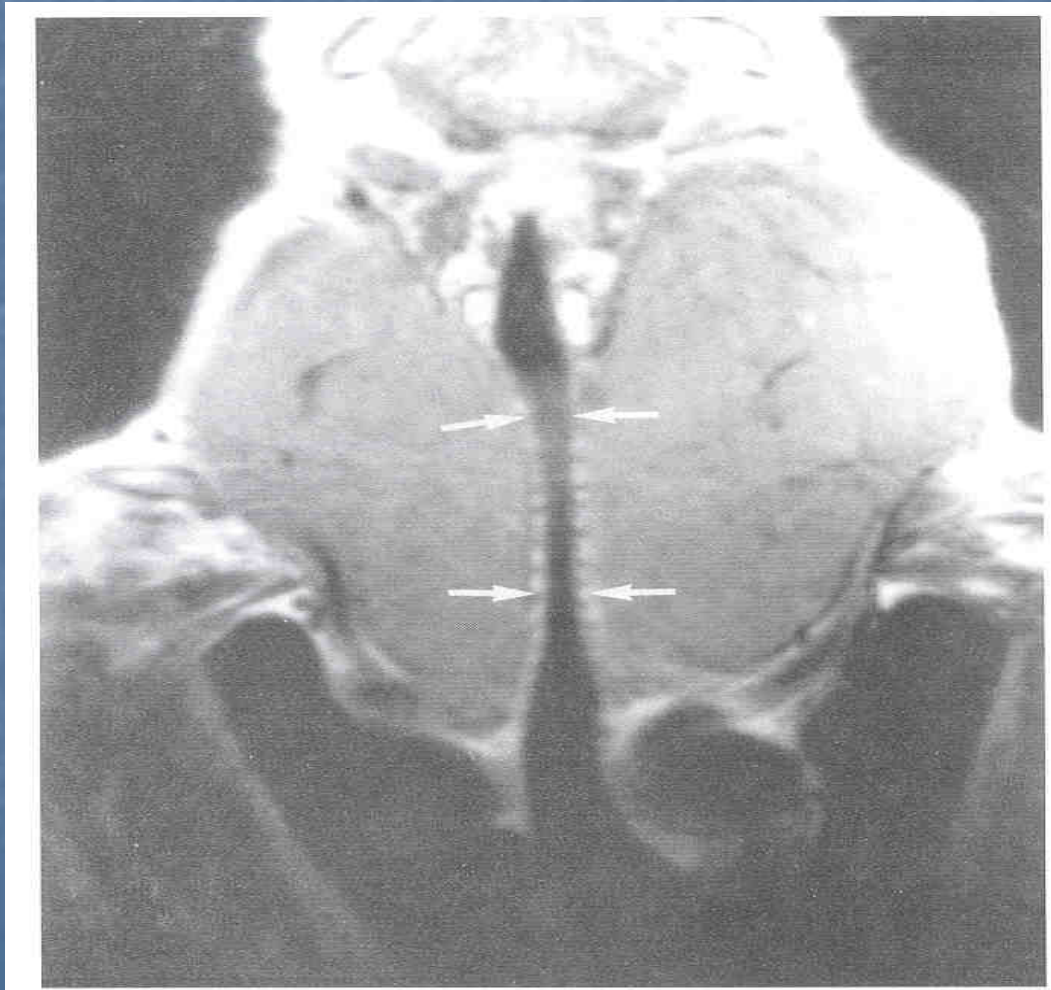- Usually picked up on routine physical exam or as incidental finding
- Patients may have clinical or subclinical thyrotoxicosis
- Patients may have compressive symptoms: tracheal, vascular, esophageal, recurrent laryngeal nerve

# Flow-Volume Loop

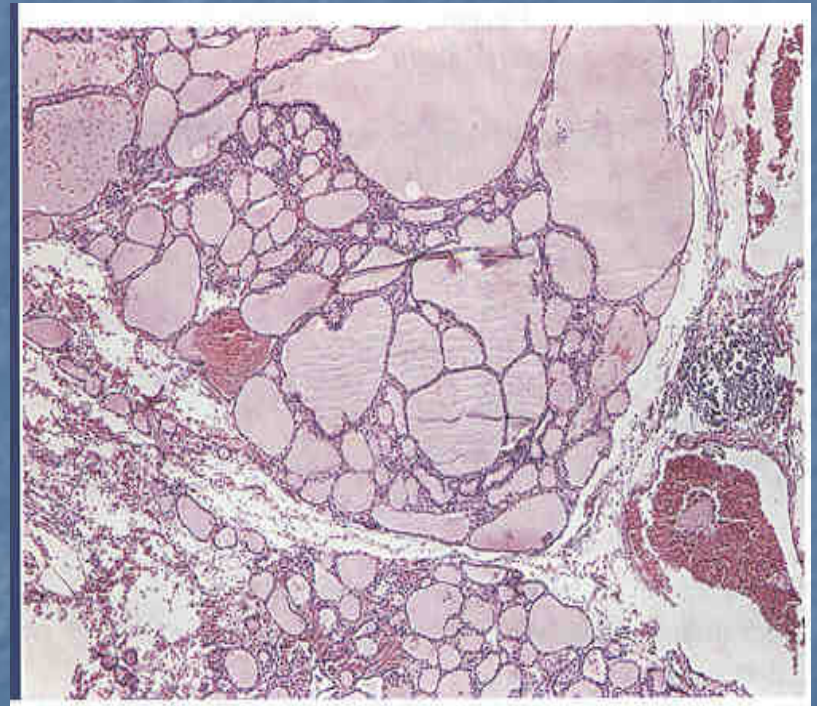
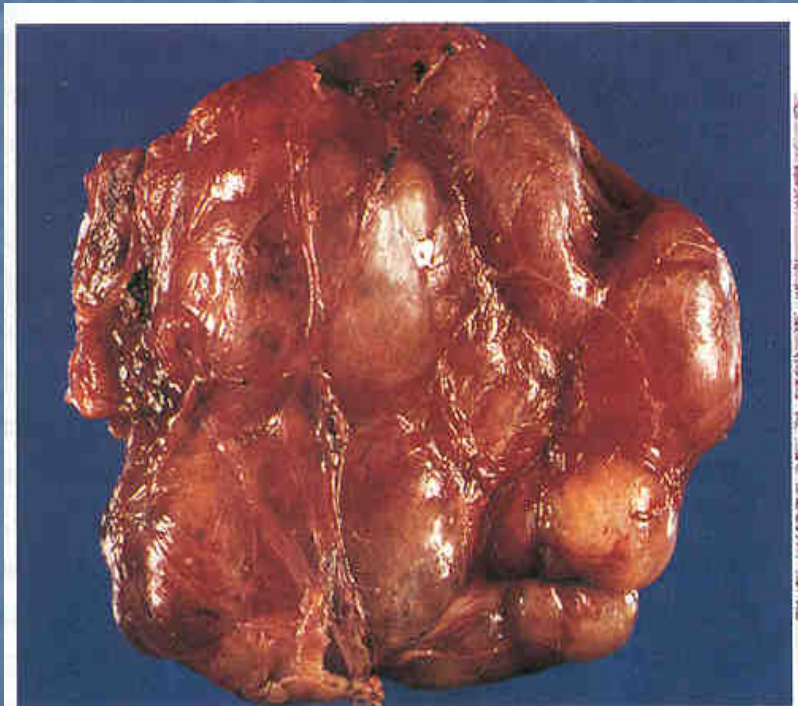

**FIG. 76.1.** Results of flow-volume loop studies in a patient with upper airway obstruction caused by a multinodular goiter before (**left**) and after (**right**) subtotal thyroidectomy. (From Miller MR, Pincock AS, Oates GD, et al. Upper airway obstruction due to goitre: detection, prevalence and results of surgical management. *QJ Med* 1990;74:177.)

# Tracheal Compression



# Gross and Microscopic Pathology Multinodular Goiter



# Treatment of Diffuse or Multinodular Goiter

- Suppressive Therapy
- Antithyroid Medications: Propylthiouracil and Methimazole
- I-131
- Surgical Therapy

# Graves' Disease

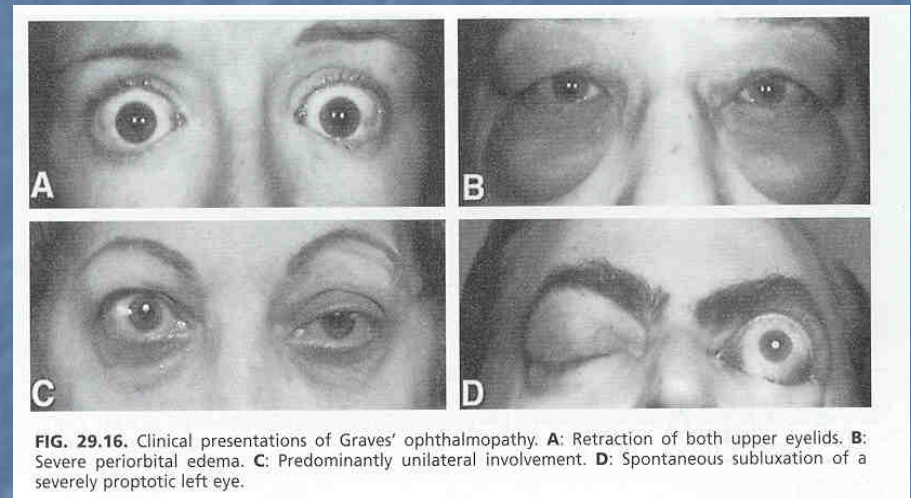
- Most common form of thyrotoxicosis
- Autoimmune etiology with familial predisposition
- Thyroid receptor stimulating antibody unique to Graves' disease; other autoantibodies present (TgAb, TPOAb)
- Affects females five times more often than males

# Presentation of Graves' Disease

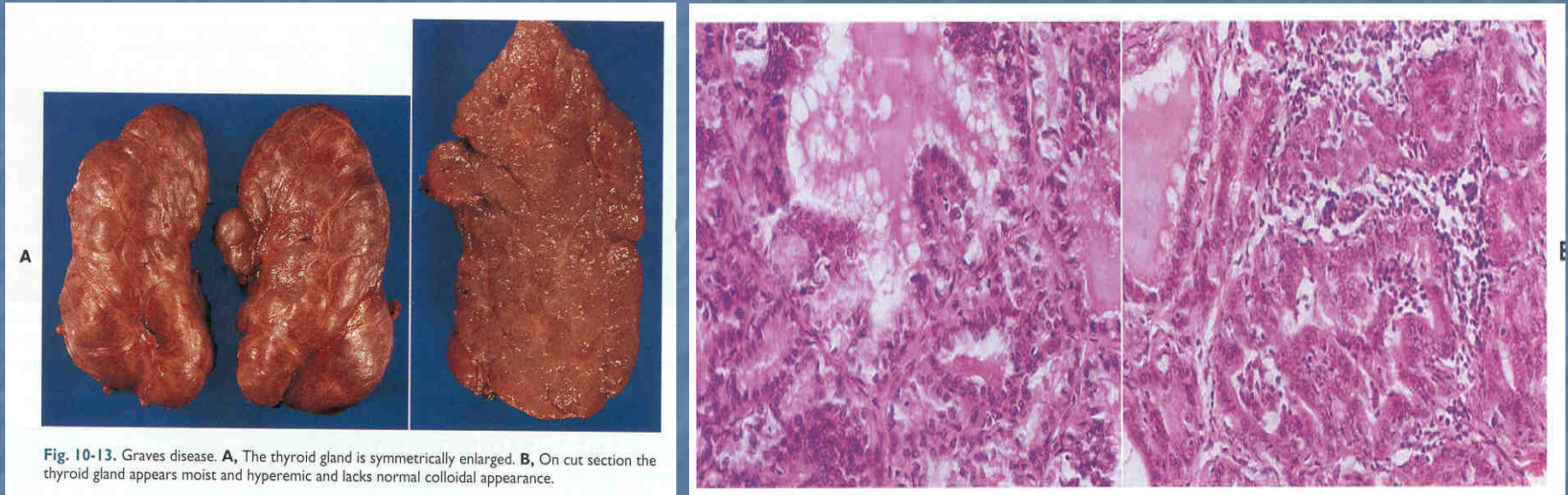
- Thyrotoxicosis: palpitations, nervousness, easy fatigability, diarrhea, excessive sweating, intolerance to heat, weight loss
- Eye signs
- Diffuse goiter

# Graves' Ophthalmopathy

- Class one: spasm of upper lids with thyrotoxicosis
- Class two: periorbital edema and chemosis
- Class three: proptosis
- Class four: extraocular muscle involvement
- Class five: corneal involvement
- Class six: loss of vision due to optic nerve involvement



# Graves' Gross and Microscopic Pathology



# Treatment

- Antithyroid Drugs
  - May require prolonged therapy
- Radioactive iodine
  - May worsen ophthalmopathy unless followed by steroids
- Surgery
  - Make patient euthyroid prior to surgery
  - Potassium iodide two weeks prior to surgery can decrease the vascularity of the gland

# Thyrotoxicosis and Thyroid Storm

- Acute thyrotoxicosis: beta-blockers, barbiturates, cholestyramine
- Thyroid storm: manage aggressively with beta-blockers, calcium channel blockers, PTU, methimazole, sodium iodide, digitalis or diuretics for heart failure, fluid and electrolyte management

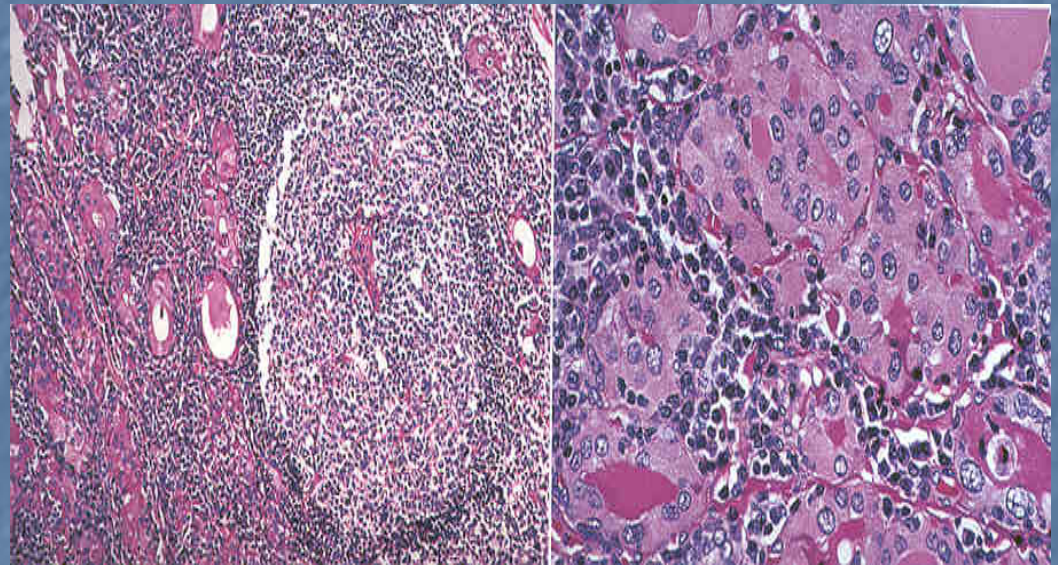
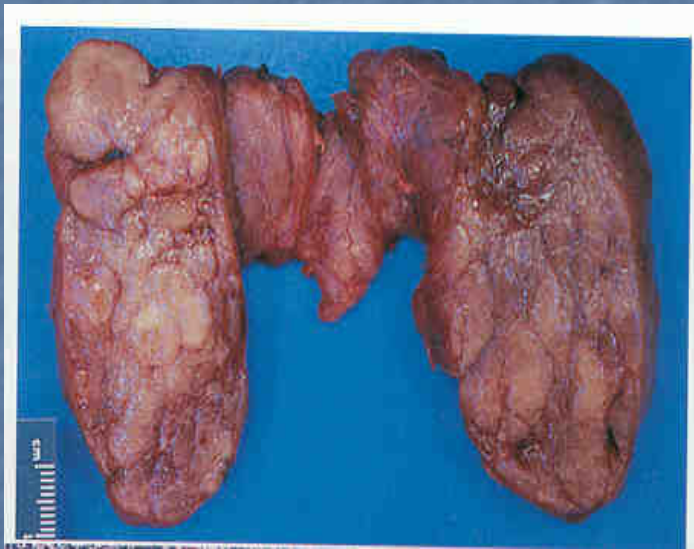# Toxic Adenoma

- Autonomously functioning thyroid nodule hypersecreting T3 and T4 resulting in thyrotoxicosis (Plummer's disease)
- Almost never malignant
- Manage with antithyroid drugs followed by either I-131 or surgery

# Chronic Thyroiditis

- Also known as Hashimoto's disease
- Probably the most common cause of hypothyroidism in United States
- Autoantibodies include: thyroglobulin antibody, thyroid peroxidase antibody, TSH receptor blocking antibody

# Gross and Microscopic Pathology of Chronic Thyroiditis



# Presentation and Course

- Painless goiter in a patient who is either euthyroid or mildly hypothyroid
- Low incidence of permanent hypothyroidism
- May have periods of thyrotoxicosis
- Treat with levothyroxine

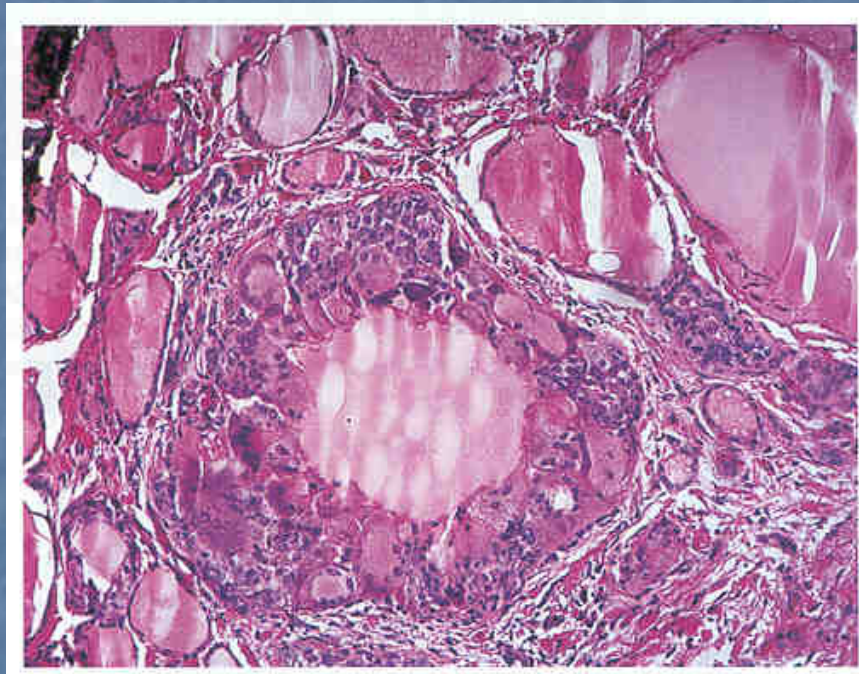
# Subacute Thyroiditis

- Also known as De Quervain's thyroiditis
- Most common cause of thyroid pain and tenderness
- Acute inflammatory disease most likely due to viral infection
- Transient hyperthyroidism followed by transient hypothyroidism; permanent hypothyroidism or relapses are uncommon

# Treatment of Subacute Thyroiditis

- Symptomatic: NSAIDS or a glucocorticoid
- Beta-blockers indicated if there are signs of thyrotoxicosis
- Levothyroxine may be given during hypothyroid phase

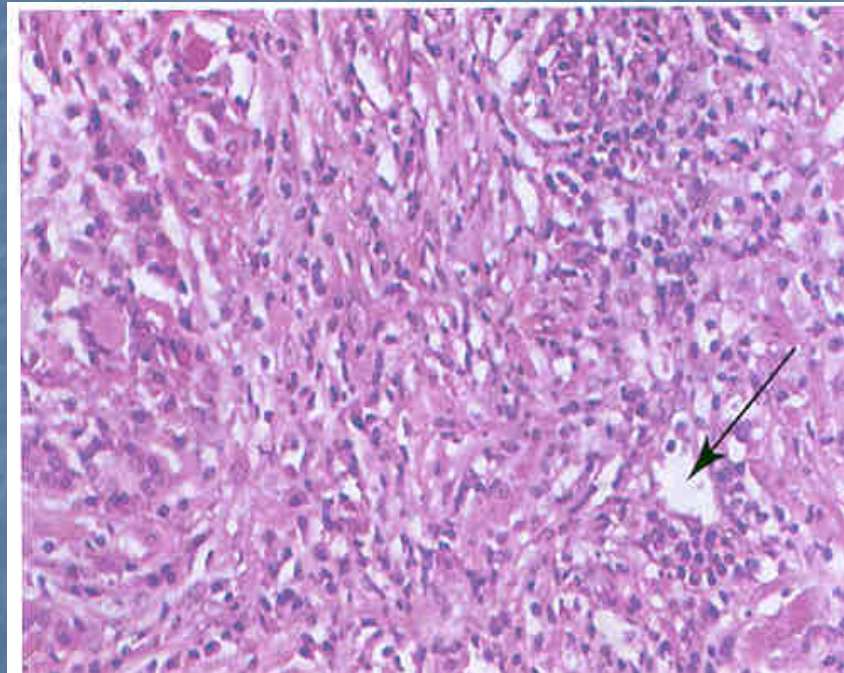
# Histopathology of Subacute Thyroiditis



# Riedel's Thyroiditis

- Rare disorder usually affecting middle-aged women
- Likely autoimmune etiology
- Fibrous tissue replaces thyroid gland
- Patients present with a rapidly enlarging hard neck mass

# Histopathology of Riedel's Thyroiditis



# Sources (photographs and figures)

- Netter FH. Atlas of Human Anatomy 2<sup>nd</sup> ed. Novartis 1997. Plate 68 and 70.
- Braverman LE and Utiger RD. Werner and Ingbar's The Thyroid A Fundamental and Clinical Text. 8<sup>th</sup> ed. Lippincott Williams and Wilkins 2000. Fig 76.1, Fig 76.2, Fig 29.16
- Damjanov I and Linder J. Pathology A Color Atlas. Mosby 2000. Fig 10-12, Fig 10-13, Fig 10-14, Fig 10-16, Fig 10-17, Fig 10-19
- Burkitt HG, Young B and Heath JW. Wheater's Functional Histology A Text and Color Atlas. Churchill Livingstone 1993. Fig 17.7
- Greenspan FS and Gardner DG. Basic and Clinical Endocrinology 6<sup>th</sup> ed. Lange 2001. Fig 7-5, Fig 7-21