

TITLE: Esophagea Dysphagia

SOURCE: Grand Rounds Presentation, UTMB, Dept. of Otolaryngology

DATE: February 6, 2008

RESIDENT PHYSICIAN: John P. Font, M.D.

FACULTY PHYSICIAN: Michael Underbrink, M.D., M.B.A.

SERIES EDITORS: Francis B. Quinn, Jr., MD

"This material was prepared by resident physicians in partial fulfillment of educational requirements established for the Postgraduate Training Program of the UTMB Department of Otolaryngology/Head and Neck Surgery and was not intended for clinical use in its present form. It was prepared for the purpose of stimulating group discussion in a conference setting. No warranties, either express or implied, are made with respect to its accuracy, completeness, or timeliness. The material does not necessarily reflect the current or past opinions of members of the UTMB faculty and should not be used for purposes of diagnosis or treatment without consulting appropriate literature sources and informed professional opinion."

Anatomy

The esophagus starts at the junction of the inferior pharyngeal constrictor and cricopharyngeus. The esophagus is about 18 to 26 cm in length ending at the distal margin of the lower esophageal sphincter (LES). The UES is formed by inferior pharyngeal constrictor and the cricopharyngeus. The LES is a thickened segment of circular smooth muscle that lies within the diaphragmatic hiatus. Structures extrinsic to the esophagus make indentations which are noted during endoscopy. These include the anterior body of C7 (worsen by osteophytes), trachea anteriorly, the arch of the aorta, the left mainstem bronchus, and the diaphragmatic hiatus.

The esophageal wall is composed of four layers: mucosa, submucosa, muscularis propria, and outermost adventitia. The esophagus has no serosa. The esophageal mucosa is lined by a nonkeratinized stratified squamous epithelium. The stomach is lined with columnar epithelium. This junction of the squamous epithelium and columnar epithelium (squamocolumnar junction) is called the Z-line. The abnormal cephalad movement of this junction is referred to as Barrett's esophagus.

The submucosa contains blood vessels, lymphatic channels, neurons of Meissner's plexus, and esophageal glands. These glands produce and secrete lubricant, mucus, and factors such as bicarbonate and epidermal growth factor that are important for epithelial defense and repair. The muscularis propria consists of both skeletal and smooth muscle. The proximal one third is skeletal muscle, the middle third is mixed, and the distal portion is smooth muscle. The muscles are arranged into inner circular and outer longitudinal layers.

The esophageal wall is innervated by both parasympathetic and sympathetic nerves. The parasympathetics regulate peristalsis through the vagus nerve. Neural innervation of the esophagus is from the myenteric (Auerbach's plexus) located between the two muscle layers and from Meissner's plexus located in the submucosa. The myenteric plexus is responsible for esophageal peristalsis. The Meissner's plexus is the site of afferent sensory input. Excitatory stimulation from acetylcholine mediates contraction of both the longitudinal and circular muscle layers. Inhibitory neurons predominantly affect the circular muscle layer via nitric oxide.

Excitatory stimulation from acetylcholine has its largest effect proximally, whereas inhibitory effect of nitric oxide is seen distally. Pain sensation arising from the esophagus overlaps with those of the heart and respiratory system, in clinical practice it may be difficult to discern the organ of origin for some chest pain syndromes.

The arterial and venous blood supply to the esophagus is segmental. The upper esophagus is supplied by branches of the superior and inferior thyroid arteries. The mid-esophagus is supplied by branches of the bronchial and right intercostal arteries and descending aorta. The distal esophagus by branches of the left gastric, left inferior phrenic, and splenic arteries. The venous drainage of the upper esophagus is through the superior vena cava, the mid-esophagus through the azygous veins, and the distal esophagus through the portal vein by means of the left and short gastric veins.

The lymphatic system of the esophagus is also segmental; the upper esophagus drains to the deep cervical nodes, the mid-esophagus to the mediastinal nodes, and the distal esophagus to the celiac and gastric nodes. These lymphatic systems are also interconnected by numerous channels, accounting for the spread of most esophageal cancers beyond the region at the time of their discovery.

Functionally, the esophagus can be divided into three zones: the UES, the esophageal body and the LES. The esophageal phase of swallowing starts with the transfer of the food bolus through the UES. As the UES closes, a progressive circular contraction begins in the upper esophagus and proceeds distally along the esophageal body. The LES relaxes as the UES closes allowing the unopposed force of the esophageal body peristalsis to propel the bolus into the gastric bed. The pressures may vary with the consistency of the bolus itself. The LES subsequently closes with a prolonged contraction, preventing movement back into the esophagus.

Secondary peristalsis is a progressive contraction in the esophageal body that is induced by stimulation of sensory receptors activated by residual food bolus or the refluxed gastric contents. This begins approximately at or above the level of the stimulus and resembles primary peristalsis. Its function is to clear the esophagus from food contents poorly cleared by the primary peristalsis and to push refluxed gastric contents back into the stomach.

Dysphagia

Dysphagia refers to the sensation that food is hindered in its passage from the mouth to the stomach. Most patients complain that food “sticks,” “hangs up,” or “stops,” or they feel that the food “just won't go down right.” It may be anatomically classified into two separate clinical categories: oropharyngeal and esophageal. Psychiatric disorders can amplify this symptom.

As part of the history it is important to clarify the origin of symptoms of esophageal dysphagia. Three questions are crucial:

- (1) What types of food or liquid cause symptoms?
- (2) Is the dysphagia intermittent or progressive?
- (3) Does the patient have heartburn?

Patients with primarily solid food dysphagia typically have a structural lesion, such as a peptic stricture, ring, or malignancy. Esophageal rings tend to cause intermittent solid food dysphagia whereas strictures and cancer cause progressive dysphagia. Those with both solid and liquid dysphagia are more likely to have a motility disorder like achalasia or scleroderma. The site at which a patient localized dysphagia is of limited value. Weight loss in a patient with dysphagia is an indicator of the significance and duration of the disease. Dietary changes in response to the dysphagia give insight into the nature and severity of disease.

Dysphagia must be distinguished from odynophagia, which refers to pain caused by swallowing. This important symptom is clearly indicative of a pharyngeal or esophageal problem. Most often this is an inflammatory condition of the esophagus such as erosive esophagitis, pill-induced esophagitis, or infectious esophagitis.

Endoscopy is the technique of choice for the evaluation of the mucosa of the esophagus and detection of structural abnormalities. Rigid esophagoscopy has long been an established method for evaluation and treatment of esophageal disorders commonly used by otolaryngologists. This procedure requires general anesthesia and provides a means to examine the full extent of the esophagus, however the view is not magnified, the esophagus is not distended, and the procedure carries both the risks of general anesthesia and the rigid esophagoscopy. Conventional flexible esophagoscopy passed transorally has used scopes with diameters approaching 1cm which provide a magnified view, suction, irrigation, and biopsy ports. The use of these scopes usually requires intravenous sedation. In the past decade manufacturers have produced flexible esophagoscopes with diameters around 5mm with digital video chip technology. These scopes provide a quality image and include the ability to suction, irrigate and biopsy. The smaller size allows their passage through the nasal cavity and the use of topical anesthesia. Without the need for intravenous sedation transforming this method into a easily performed clinic procedure and the patient can returned to work after the appointment. Another benefit of flexible esophagoscopy is that it allows the insufflation of air to distend the esophagus and more easily see all of the mucosa.

The transnasal-esophagoscope procedure starts with the application of topical anesthesia to both the nasal and oral cavity. The scope was advanced through the nose into the oropharynx. Velopharyngeal closure, anatomy of the base of the tongue and hypopharynx, vocal cord motion, status of the pharyngeal musculature, and patient's ability to manage their own secretions was noted. With the scope above the cricopharyngeus the patient was asked to burp or swallow to allow passage of the scope. The scope was then advanced to the gastroesophageal junction taking care to note any abnormalities. The squamocolumnar junction (SCM) can be recognized by the irregular **Z** line, demarcating the interface between the light pink esophageal squamous mucosa and the red columnar gastric mucosa. The GEJ is defined by the proximal margin of the gastric folds. Although the SCM and GEJ are normally located at the same level, the two are not synonymous. In patients with Barrett's esophagus, the SCM is more proximal in the esophagus than the GEJ. Endoscopy can also be used to diagnose the presence of hiatal hernia.

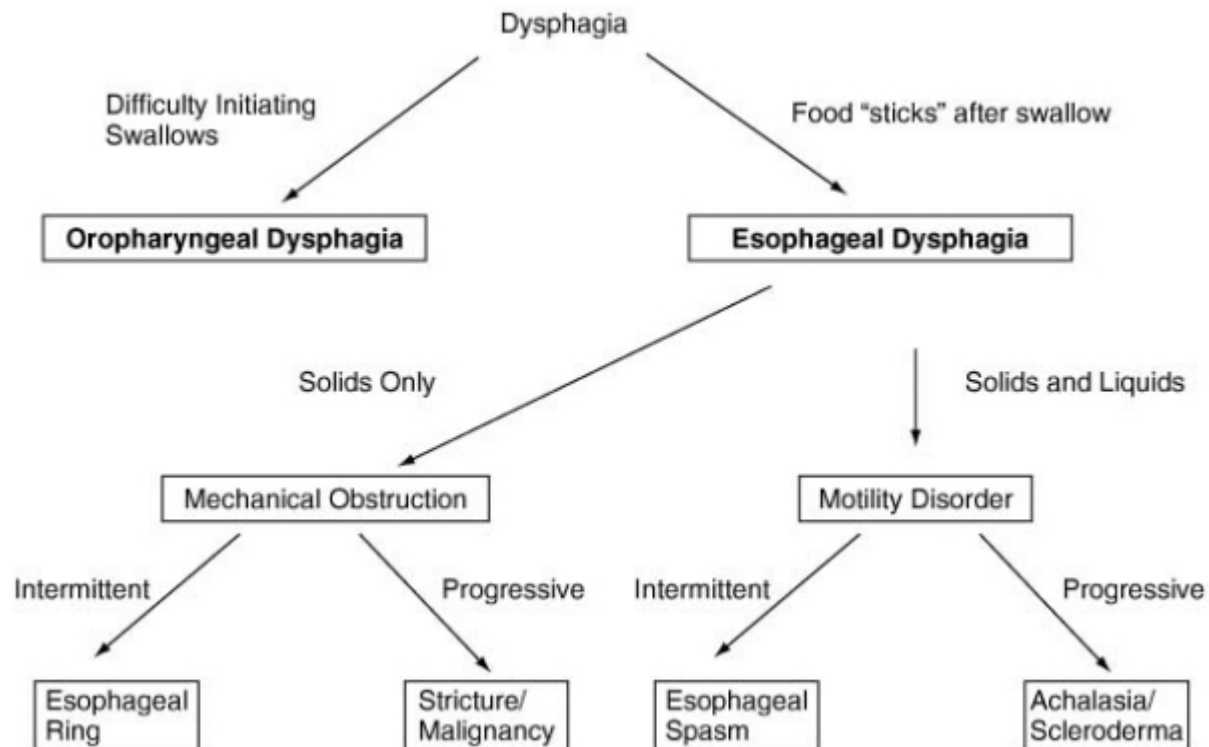
Aviv et al in 2001 reported their experience with transnasal esophagoscopy. They performed exams on 14 consecutive patients with dysphagia. Patients were asked to avoid aspirin, aspirin-like compounds, and vitamin E for two weeks prior to the procedure in case

biopsies were necessary. The exams were performed in the otolaryngologist's office with the patient in a standard examining chair. A 4.9mm outer diameter endoscope was used. Biopsies were then performed if necessary. They had patients rate the discomfort of the exam on a scale from one to ten (with one being no discomfort). Overall tolerance was rated as a 2 by the patients. All patients stated they would be willing to repeat transnasal esophagoscopy if recommended by their physician. Authors from the Department of Otolaryngology at Wake Forest University have published several articles on their experience with transnasal esophagoscopy. Postma et al in 2005 published their review of 711 consecutive patients examined with transnasal esophagoscopy. They used a spray combination of 0.05% oxymetazoline and 4% lidocaine in the nasal cavity. If biopsy or a longer procedure is required, one Tessalon Perle is used. Seventeen of 711 procedures (3%) were terminated due to a tight nasal vault and 2 due to a self-limited vasovagal response. 100 of the patients were included in a prior report. Of the 592 completed exams in the newest series of patients, there was a 50% incidence of significant findings.

Esophageal manometry is a diagnostic test that measures intraluminal pressures and coordination of the pressure activity of the three functional regions of the esophagus: the LES, esophageal body, and the UES. Manometry uses a catheter that measures pressures at various intervals along the length of the esophagus. With each swallow, data on strength, timing, and sequencing of pressure events are obtained. The advantage of the study is that it is an actual test of pressure wave physiology. The disadvantages of the study are that it is not widely available, cannot diagnose visible lesions, is unpleasant, and is a technically demanding study to perform. For these reasons this study is rarely used except in cases where elevated intraluminal pressures must be followed (e.g. achalasia). The study may be indicated for patients who need recurrent intraluminal pressure assessment for achalasia or diffuse esophageal spasm.

The barium esophagram involves the use of a cup of liquid barium that is swallowed, then followed fluoroscopically to the stomach. Because the study is documented only on plain film, it is not considered a dynamic swallow study. The air contrast esophagram uses effervescent granules followed by administration of barium to provide better anatomic detail. The advantages of the study are that it is widely available, and with air contrast it provides better anatomic detail. The disadvantages are that the study involves radiation exposure, the logistics are difficult in bedridden patients, and the study is not a dynamic one so it cannot adequately detect dynamic dysfunction. The study is indicated in patients in whom structural disorders are suspected (e.g. dysphagia to solid foods and not to liquids) because of its relatively good level of anatomic detail.

Videofluoresophagography is the procedure of choice as it allows a frame-by-frame evaluation of the rapid sequence of events involved in transfer of the bolus from the mouth to the esophagus. Endoscopic examination is considered mandatory in all patients with esophageal dysphagia. However, contrast esophagography may also be helpful; it can provide guidance for endoscopy that is anticipated to be difficult (e.g., a patient with a complex stricture), suggest a disturbance in motility, and occasionally detect subtle stenoses that are not appreciated on endoscopy (the scope diameter is typically 10 mm or less, whereas some symptomatic strictures can be considerably wider).



Dysphagia evaluation algorithm

Cummings: Otolaryngology: Head & Neck Surgery, 4th ed

Achalasia

Achalasia is a esophageal motility disorder cause by loss of postganglionic inhibitory neurons of the myenteric plexus leading to insufficient LES relaxation and loss of esophageal peristalsis. The symptoms of achalasia include dysphagia for solids and liquid, regurgitation, and chest pain.

If achalasia is suspected, a barium esophagram with fluoroscopy is the best initial diagnostic study. This test will reveal a dilation of the proximal esophagus with loss of primary peristalsis in the distal two thirds of the esophagus. There is a smooth tapering of the lower esophagus leading to the closed LES, resembling a bird's beak. Esophageal manometry will confirm increased intraluminal pressure along the LES with loss of peristaltic wave along the distal esophagus. About 70% to 80% of patients have incomplete LES relaxation with swallows. Endoscopy should be performed to rule out a distal malignant esophageal stricture. The two most effective treatments are graded pneumatic dilation and surgical myotomy. All patients considered for pneumatic dilation should be surgical candidates because the procedure is associated with a 2% to 5% risk of perforation. Studies to date indicate good-to-excellent relief of symptoms in 50% to 93% of patients using the graded dilators. Myotomies are increasingly being performed by laparoscopy with a good-to-excellent response rate of 80% to 94%. For patients who are at high risk for pneumatic dilation or surgery, endoscopic injection of the LES with botulinum toxin (Botox) or pharmacologic treatment with nitrates or calcium-channel blockers may be acceptable alternatives.

Diffuse esophageal spasm (DES)

Diffuse esophageal spasm (DES) is characterized by simultaneous and repetitive contractions in the esophageal body on manometric studies. LES relaxation is also normal in DES. The classic finding on esophagogram is the "corkscrew" esophagus. Patients with DES may present with chest pain or dysphagia. The treatment of DES consists of medications that relax the esophagus, such as nitrates and calcium-channel blockers, but is usually not completely effective. Secondary motility disorders are commonly a result of systemic conditions. The most common condition affecting esophageal motility is scleroderma.

Strictures

An esophageal stricture is defined as any loss of lumen area within the esophagus. The normal esophagus measures 20 mm in diameter. The predominant clinical symptom of strictures is dysphagia, which is usually most prevalent when the lumen diameter is less than 15 mm. The most common cause of strictures is acid/peptic cause accounting for the majority of cases (60%–70%). The treatment of benign stricture disease is esophageal dilation. Tight or complex strictures such as those less than 10 mm in diameter or greater than 2 cm in length are best managed with wire-guided dilation under fluoroscopic and endoscopic control. Simple strictures can be dilated with Maloney dilators that are passed orally. Esophageal dilation is performed progressively over weeks to months with a gradual increase in the diameters of the dilators. Most patients have relief of dysphagia after dilation to a diameter of 40 to 54 French or 13 to 17 mm with no requirement for maintenance dilations. Those with radiation-induced or malignant strictures are at higher risk of perforation. To minimize the risk of perforation, the "rule of threes" applies. That is, no more than three sequential dilators should be performed per session. Refractory strictures can be treated endoscopically with injection of triamcinolone into the stricture in all four quadrants prior to dilation. More recently, endoscopically placed temporary nonmetallic expandable stents (Polyflex) were effective in the treatment of refractory benign strictures.

RINGS AND WEBS

Esophageal rings and webs are common findings on upper endoscopy, and many are asymptomatic. Symptoms can include intermittent solid food dysphagia, aspiration, and regurgitation. Rings are circumferential, can consist of mucosa or muscle, and most commonly occur in the distal esophagus. Esophageal webs occupy only part of the esophageal lumen, are always mucosal, and are usually located in the proximal esophagus. Barium radiography is the most sensitive test to diagnose esophageal webs. Endoscopic dilation is usually effective in the management of these patients. Cervical webs are associated with carcinoma and warrant endoscopic evaluation and biopsy. Schatzki's ring occurs at the GEJ at the distal margin of the LES and is the most common cause of intermittent solid food dysphagia and food impaction. Some authors believe the rings are congenital lesions, whereas others suspect a role for GERD.

Dysphagia lusoria

Dysphagia lusoria is the term given for symptoms arising from vascular compression of the esophagus by an aberrant right subclavian artery. The right subclavian artery in this

circumstance arises from the left side of the aortic arch and courses from the lower left to the upper right side posterior to the esophagus. Typically, the diagnosis is established by barium esophagogram, which shows the characteristic pencil-like indentation at the level of the third and fourth thoracic vertebrae. Confirmation is by CT, MRI, arteriography, or EUS. During endoscopy the right radial pulse may diminish or disappear from instrumental compression of the right subclavian artery. Symptoms usually respond to simple modification of the diet to meals of soft consistency and small size.

Gastroesophageal Reflux Disease

GERD is recognized in about 10-15% of the population. The disease does not typically cause dysphagia, so other causes should be explored. The cause of GERD is related to incompetence of the lower esophageal sphincter. Regurgitation of stomach contents may cause sensation of subxyphoid pressure. Severe disease may lead to stricture formation, Barrett's esophagus, and increased risk of esophageal cancer. Radiography shows evidence of lower esophageal sphincter incompetence or sliding hiatal hernia in 1/3 of patients. Indirect laryngoscopy may show interarytenoid erythema or edema. Manometry shows decreased lower esophageal sphincter tone. The gold standard for diagnosis is the 24 hour pH probe. Treatment is with anti-reflux medications such as H₂ blockers and proton pump inhibitors along with life-style modifications.

Ambulatory 24-hour esophageal pH monitoring is an important tool in the diagnosis and management of GERD. Esophageal pH monitoring can detect and quantify gastroesophageal reflux and correlate symptoms temporally with reflux. The *Bravo* pH probe is a catheter-free monitoring system in which a pH monitoring probe approximately the size of a medication capsule is placed endoscopically.

Endoscopy is the technique of choice to evaluate the mucosa in patients with symptoms of GERD. Reflux esophagitis is present when erosions or ulcerations are present at the SCM. There are many grading systems to characterize the severity of esophagitis, the most common of which is the Los Angeles classification.

The goals of treatment in GERD are to relieve symptoms, heal esophagitis, prevent recurrence of symptoms, and prevent complications. A variety of lifestyle modifications are recommended in the treatment of GERD. These include avoidance of precipitating foods (fatty foods, alcohol, caffeine), avoidance of recumbency for 3 hours postprandially, elevation of the head of the bed, smoking cessation, and weight loss. The cornerstone of GERD therapy is the administration of agents that decrease gastric acid secretion, such as H₂ blockers and proton pump inhibitors, thereby decreasing esophageal acid exposure. Treatment is with anti-reflux medications along with life-style modifications.

Barrett's esophagus is a potentially serious complication of long-standing GERD. Barrett's esophagus is present when the normal stratified squamous epithelium of the distal esophagus is replaced by intestinal columnar metaplasia. It is the most significant outcome of chronic GERD and predisposes patients to the development of esophageal adenocarcinoma.

Malignant Stricture

Approximately 12,000 cases of esophageal carcinoma occur in the United States each year. Squamous cell carcinoma (SCC) is typically a disease of black males and is associated with alcohol and tobacco abuse. Persons with a past history of caustic esophageal injury are also clearly at increased risk. Other conditions including achalasia, Plummer-Vinson syndrome, ptyalism, and a history of head and neck SCC may also confer increased risk. Esophageal dysplasia and SCC have also been associated with human papillomavirus. On the other hand, adenocarcinoma is predominantly a disease of white males and has a well-documented association with GERD and Barrett's esophagus. Malignant obstruction because of esophageal carcinoma is a late presentation and carries a poor prognosis. Dysphagia is rapidly progressive. Tissue diagnosis can be made by endoscopy with mucosal biopsy. Evaluation includes staging of the disease with computed tomography and endoscopic ultrasound.

Cricopharyngeal Achalasia

A prominent cricopharyngeus can cause dysphagia by failure of adequate opening of the pharyngoesophageal segment. This failure to open occurs secondary to failure of pharyngeal and laryngeal elevation during swallowing, abnormal cricopharyngeal contraction, or inflammatory (e.g. gastroesophageal reflux disease, GERD) or neoplastic process. Symptoms range from a "globus" sensation to significant dysphagia with pooling of secretions and aspiration. Medical therapy includes treatment of GERD and Botox injection into the cricopharyngeus for temporary relief. If Botox works to correct dysphagia, cricopharyngeal myotomy may provide more permanent relief. In this somewhat controversial procedure, a careful releasing scalpel incision is made in the cricopharyngeal muscle avoiding mucosal damage. In properly chosen patients, this procedure has a high success rate. Patients with clear signs of cricopharyngeal spasm/hypertrophy on radiology and manometry are most likely to benefit.

Zenker's Diverticulum

The Zenker's diverticulum is an acquired mucosal herniation through a posterior portion of the cricopharyngeus in an area of congenital weakness in the muscle known as Killian's dehiscence. Symptoms caused by the diverticulum include coughing up undigested food, aspiration, and chronic mucus production. Small diverticula can be treated by cricopharyngeal myotomy alone. Larger diverticula require dissection off of the rest of the esophagus and transection with the defect sutured in layers. Diverticulopexy, or suspension of the diverticulum vertically in pre-vertebral fascia is used to shorten the procedure and reduce risk in high risk elderly patients. Endoscopic techniques use a variation of the Van Overbeek's diverticuloscope and the CO₂ laser to perform the diverticulotomy. The GIA stapler can also be used to divide and secure the pouch endoscopically.

References

- Bechi P: Long-term ambulatory enterogastric reflux monitoring: validation of a new fiberoptic technique. *Dig Dis Sci* 1993; 38:1297-1306.
- Devault KR, Castell DO: Updated guideline for the diagnosis and treatment of gastroesophageal reflux disease. *Am J Gastroenterol* 1999; 94:1434-1442.
- Elluru RG, Willging JP. Endoscopy of the Pharynx and Esophagus. Cummings CW, ed. Otolaryngology Head & Neck Surgery. Philadelphia: Elsevier Mosby; 2005, 1825-1834.
- Mittal RK: Transient lower esophageal sphincter relaxation. *Gastroenterology* 1995; 109:601-610
- Postma GN, Cohen JT, Belafsky PC, et al. Transnasal Esophagoscopy: Revisited (over 700 Consecutive Cases). *Laryngoscope* 2005;115:321-323.
- Postma GN, Bach KK, et al. The Role of Transnasal Esophagoscopy in Head and Neck Oncology. *Laryngoscope* 2002;112:2242-2243.
- Tobin RW: Esophageal rings, webs, and diverticula. *J Clin Gastroenterol* 1998; 27:285.
- Vaezi MF, Richter JE: Diagnosis and management of achalasia. *Am J Gastroenterol* 1999; 12:3406-3413.
- Vollweiller JF, Vaezi MF. The Esophagus: Anatomy, Physiology, and Diseases. Cummings CW, ed. Otolaryngology Head & Neck Surgery. Philadelphia: Elsevier Mosby, 2005, 1835-1998.