

TITLE: Lip Cancer Reconstruction

**SOURCE: Grand Rounds Presentation, University of Texas Medical Branch
(UTMB Health), Dept. of Otolaryngology**

DATE: December 2011

RESIDENT PHYSICIAN: Naren Venkatesan, MD

FACULTY PHYSICIAN: Raghu Athre, MD

SERIES EDITOR: Francis B. Quinn, Jr., MD

ARCHIVIST: Melinda Stoner Quinn, MSICS

"This material was prepared by resident physicians in partial fulfillment of educational requirements established for the Postgraduate Training Program of the UTMB Department of Otolaryngology/Head and Neck Surgery and was not intended for clinical use in its present form. It was prepared for the purpose of stimulating group discussion in a conference setting. No warranties, either express or implied, are made with respect to its accuracy, completeness, or timeliness. The material does not necessarily reflect the current or past opinions of members of the UTMB faculty and should not be used for purposes of diagnosis or treatment without consulting appropriate literature sources and informed professional opinion."

Introduction:

This talk will focus on the understanding the basics of lip cancer and becoming familiar with common reconstructive options that may be used following resection. Following an introduction with anatomy and functional considerations, basic highlights regarding diagnosis, staging, and management of lip cancer will be discussed. This will be followed by a listing of the various reconstructive options – detailing their indications and limitations.

Anatomy

The lip anatomy is complex especially when trying to understand the important landmarks used in skin as well as the underlying muscle. When viewing the patient's face, it is important to identify the melolabial and labiomandibular creases as they help separate the region of the lip from the cheek. The lip, itself, can be divided into a mucosal portion called the red lip and a skin portion, the white lip. This distinction is important as will be seen later when understanding the pathology and location of lip cancers. The vermilion border is a unique structure in the head and neck region and one that cannot be recreated. Therefore, it is essential to note if it is obscured or involved by a cancer. It is also of importance to reapproximate the vermilion border when at all possible.

Two other structures to keep in mind are the mental crease and the philtral ridges along with the philtrum. In these cases, reconstruction follows resection of a cancer where closure with form and function are of greatest importance. However, keeping mind of such other defining landmarks and features can add an improved aesthetic aspect following resection when at all possible.

Underneath the skin, there is a complex framework of facial muscles which help provide function and oral competence. The orbicularis oris muscle should be easily noted and must always be addressed as it provides the key function of oral closure. In addition, the lip has several key elevators, including the Risorius, Zygomaticus Major, Zygomaticus Minor, Levator Anguli Oris, and Mentalis muscles. The Platysma, Depressor Anguli Oris, and Depressor Labii Inferioris are the primary depressors of the lip. The Buccinator muscle lying deep to the Risorius is also an important muscle to be aware of due to its role in identification of vascular structures.

The major arterial supply begins with the facial artery, a branch of the external carotid artery. The facial artery courses over the body of mandible before making an upward ascent to the commissure where it is typically found within 1-2cm. The Facial artery runs deep to the risorius and superficial to the

buccinators muscles. At the commissure, facial artery separates into an Inferior Labial artery and a Superior Labial artery. The Superior Labial artery gives off the Angular artery near the commissure. The Superior Labial artery runs deep to Zygomaticus Major after giving off the Angular artery after which it enters orbicularis oris. The Superior Labial artery continues to run along upper lip and anastomoses with opposite side. The Inferior Labial Artery arises as a branch from the Facial Artery near the commissure and runs deep to Depressor Angularis Oris. It enters the Orbicularis Oris and runs along lower lip to anastomose with opposite side.

Having understanding of the anatomical background is important, but an understanding of the functional role of the lips is also integral when assessing for reconstruction. The lips play an important role in oral competence, deglutition, expression of emotions, and speech. Without the lips, the consonants –“b, m, w, p” (purely labial) and “f, v” (labio-dental) could not be pronounced. A key factor to consider for functional importance is the patient’s dentition. Edentulous patients pose an important challenge to reconstruction as only a mild degree of microstomia may be acceptable if dentures are worn.

Lip Cancer Staging and Treatment

Some basic lip cancer facts are that lip cancer incidence is about 1-2% of all cancers and is the most common oral cavity cancer. The major risk factors for developing lip cancer are prolonged sun exposure, male gender, pipe-smoking/tobacco chewing, and alcohol consumption. When categorizing lip cancer, the rule of the 90s can be helpful. 90% of lip cancer is on the lower lip. 90% of lip cancer is squamous cell carcinoma. 90% of lip cancer is found on the red (mucosal) lip. Lip cancer has an excellent prognosis if diagnosed and treated when less than 2 cm. While squamous cell cancer arises mainly on the red lip, basal cell carcinoma, the next most common, arises mainly on the white lip. The rarer types of lip cancer that may occur include adenocarcinoma secondary to minor salivary gland presence, melanoma, lymphoma, and sarcoma if the underlying muscle is the source of the cancer.

When deciding treatment, it is also important to understand the spread of lip cancer to lymph nodes. The main difference between cancer being present in the upper or lower lip is the different pattern of spread. Due to embryologic fusion in the midline of the upper lip, there is no contralateral spread with regards to neck lymph nodes. The lymph nodes involved are always levels I, II, and III primarily. The upper lip therefore spreads to only the ipsilateral levels while the lower lip spreads to ipsilateral and contralateral lymph nodes.

Lip cancer is staged as are all oral cavity cancers. The primary decision is size and once greater than 4cm if adjacent structures are involved. A T1 tumor is less than 2 cm. A T2 tumor is between 2 and 4 cm. A T3 tumor is greater than 4 cm. A T4 tumor is considered once that invades adjacent structures such as skin, cortical bone, or through floor of mouth. The T4b stage is reserved for those tumors considered unresectable due to involvement of critical structures.

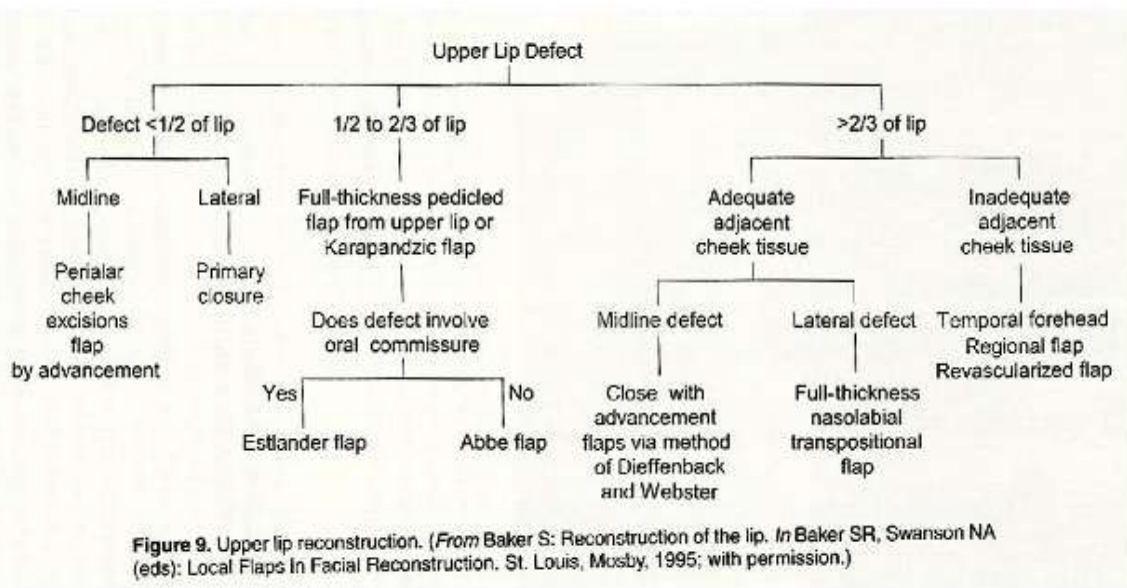
For lip cancer, surgical treatment is the mainstay of therapy. For any size primary cancer, a 0.5 cm margins around tumor is necessary. Due to the high correlation of spread following increasing size, especially with T2 or larger lesions, a neck dissection is often performed in conjunction, particularly if lower lip cancer which has a higher incidence of spread with smaller lesions. For an N0 neck, an elective Supraomohyoid neck dissection can be performed. For clinically present nodal disease, a selective Levels I-IV neck dissection is recommended.

Radiation Therapy has a role in treatment of lip cancer although surgery is the mainstay of treatment, as is the case with oral cavity cancer. Radiation therapy may be used as primary treatment if T1 or non-operable patient. It may also be used for patients with post-operative XRT for advanced stages, cases with close margins, or where pathology demonstrated extracapsular extension or perineural/intravascular invasion.

Reconstruction

This is a tough area to explain solely with words. In the power point, there are numerous pictures detailing the following surgical options.

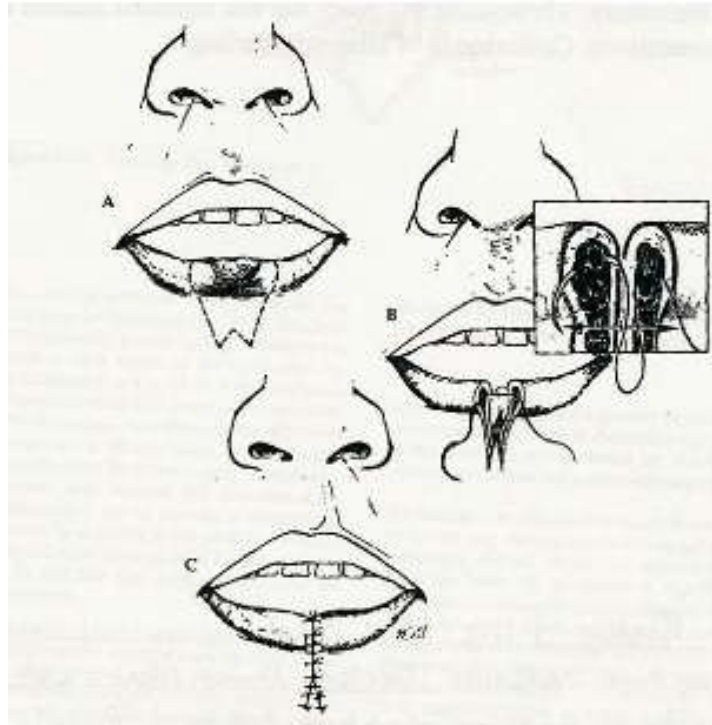
With either the upper or lower lip, the key step to decide in the algorithm is the size of the defect that you will be left with after resection. Further, understanding the location of the defect to better understand if adjacent cheek tissue can be used will help in planning of reconstruction for large defects. Sample algorithm for upper lip defects is shown in the diagram below from Baker – Local Flaps in Facial Reconstruction.



A lower lip algorithm would be quite similar to this one with a key exception being that primary reconstruction would be preferred for any small defect of the lower lip, regardless of size. The lip tissue is unique to the face where there is no similar tissue to recreate the vermilion border as well as orbicularis oris and its role in oral competence.

Primary closures can be done either by designing a local V to Y flap or by performing a wedge resection. When considering the wedge resection, it is important to understand how the closing scar will be and whether it will interfere with surrounding skin creases. In the lower lip, the mental crease is a key aesthetic structure. When designing the resection, a W- shaped incision can provide for a more tailored closure than a direct V-shaped wedge. The W-shaped wedge will close in an upside down Y shape. The arms of the Y can be angled to avoid the crease or can be made to be slightly asymmetric so that a smaller scar can be achieved. A key restriction to the use of primary closure for a small defect is the

involvement of the commissure. Due to the inability to recreate the commissure, a decision will have to be made regarding creation of a neo-commissure. The other important thing to remember for primary closure techniques is to re-approximate the vermillion border well and bring together the underlying orbicularis muscle to ensure a good functional and aesthetic outcome.



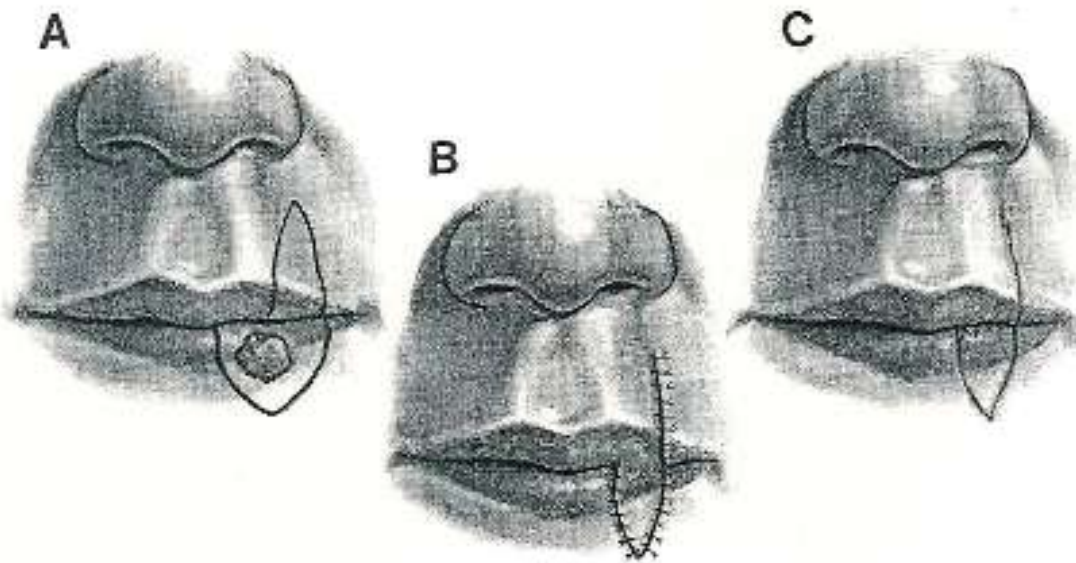
From Baker – Local Flaps in Facial Reconstruction

When deciding on reconstruction of a larger defect, the first question to decide is the amount of tissue availability locally. First, decide if the defect is so large that a free flap may be required. If not, then decide if adjacent cheek tissue will be needed. This concern may be present even in a smaller size defect if it is located laterally or near the commissure. After having answered these questions, decide amongst the following choices: mucosal advancement flap, Abbe flap, Estlander-Abbe flap, Karapandzic flap, Gilles Fan flap, or the preferred free flap of the radial forearm.

The Mucosal Advancement flap is used only for lesions involving the red lip. Due to the pull up of the mucosa to the vermillion border, the border can be preserved. The key surgical step is to undermine labial mucosa deep to minor salivary glands and superficial to the posterior aspect of the orbicularis oculi. Extensive undermining will allow for closure. Further, if more extension is needed, the flap can be undermined into the gingivobuccal sulcus providing further laxity. There are several concerns with regards to the flap. First, the advanced mucosa may end up displaying a deeper red color than the natural vermillion. For women, this may provide an enhanced aesthetic outcome, but this development may be a concern for men. Second, it is tough to incorporate this flap if any skin of the lip is involved. This flap should still be used but may be challenging as it will be difficult to approximate the vermillion border. Lastly, contracture of the flap can lead to inversion of the lip so it is of key importance to undermine as much as possible when elevating the flap to prevent the inversion.

The Abbe and Estlander-Abbe flaps are similar flaps designed from the principle of a pedicled cross lip flap. For the Abbe flap, the principle is to create a pedicle from the lip without the lesion to the area of the defect on the opposite lip. This flap is based on the arterial supply of the labial artery – either the superior or inferior. The flap is ideal for lesions involving 1/3 – 2/3 of the lip. Also, lesions must not involve the commissure.

The surgical steps of the Abbe flap are as follows. First, draw defect on affected lip. The defect should be aimed in a shape much like a petal or a “V” with the lines slightly bowed outwards. Then, draw the flap on the opposite lip to be half the width of the defect in a similar shape. The flap should be just across the defect on the opposite lip. Make the full-thickness incision – cut through the skin, orbicularis oris, and mucosa. Then, rotate the flap 180 degrees and suture flap with each individual layer. Finally, dress the wound to minimize tension as the flap will remain in place until division of the pedicle approximately 2-3 weeks following the procedure.



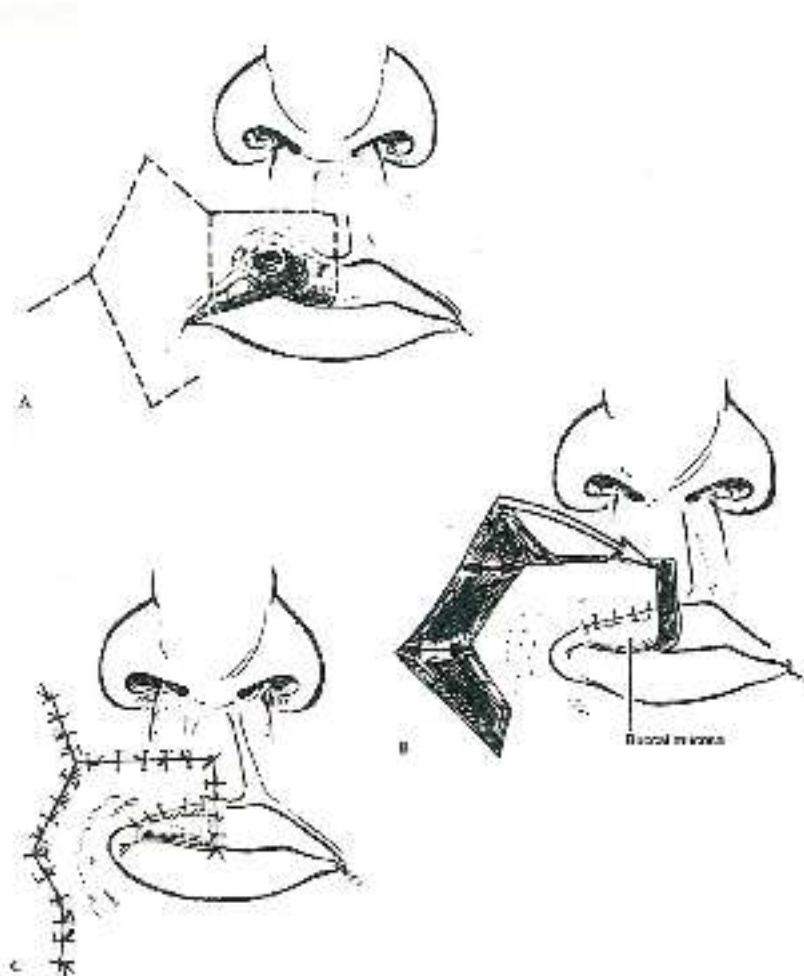
From Papel I. – Facial Plastic and Reconstructive Surgery. Chapter 51: Lip Reconstruction

The Estlander flap is quite similar to the Abbe flap with the key difference that it takes into consideration defects that involve the oral commissure. The principle is the same in creating a cross lip pedicled flap. The key difference is that the rotation occurs around the commissure. It is drawn in a similar fashion with the flap being half the size of the defect. The key disadvantage of these flaps is that they do not provide good functional outcome despite providing a good aesthetic outcome.

The best flap in this category for treating large defects but preserving functional outcome is the Karapandzic flap. It is a fairly recently designed flap by Dr. Karapandzic in the former Yugoslavia in 1974. As a local flap, it also works on the principle of local arterial supply by using the labial artery. Its main indications include use for the following: defects less than 1/2 of upper lip, defects less than 2/3 of lower lip, full thickness defects, and best suited when a rectangular defect can be constructed on the central lower lip following resection.

The key surgical steps begin with drawing the incision around the defect and continuing the incisions into the nasolabial fold superiorly in the case of a lower lip defect. Then, raise only skin and mucosa then rotate the flap as a full thickness flap using the orbicularis oris. If further movement is needed, the surgeon may selectively cut portions of the orbicularis oris near the original commissure. The main advantage of the Karapandzic flap is that it preserves perioral sensation and function of the orbicularis oris by saving CN V₃ and VII. The main disadvantage is risk of microstomia which is directly proportional to size of defect.

The Nasolabial Transpositional Flap is also called the Gilles Fan flap. It is a rotation-advancement flap. It is also based of the labial artery. The flap is preferentially used in upper lip lesions as the flap can be rotated around the commissure. The result of the flap will be a neo-commissure.



In the Gilles Flap, the key surgical steps are the following. Start with a full thickness incision medial to defect. Then, continue the full thickness incision laterally and around the commissure. Follow the melolabial fold as this crease will be recreated. Then, carry the incision down to the superior vermilion border. Advance the flap and suture individual layers together.

If the defect is sufficiently large, a free flap may be necessary in order to fill the defect. Of the choices, the radial forearm free flap is selectively chosen. An added benefit of using the radial forearm free flap is the incorporation of the Palmaris longus tendon. The Palmaris longus tendon can be used to secure to the maxilla in order to provide tension to the flap. This tension helps to make sure that the reconstructed lip can help retain secretions and decrease dripping/drooling of saliva. The skin paddle from the radial forearm free flap can be used to cover the lip skin and oral mucosal defect. The Palmaris longus tendon is usually transected within 5 m of either end of the flap.

Conclusion

The reconstruction of lip defects remains an interesting and complicated area of the face. The functional importance of the lips play a significant role. The functional importance is the fundamental goal of reconstruction; however, due to the prominence of the surgical site, obtaining the best aesthetic outcome should be a close second goal. In the case of small cancers, a good aesthetic outcome should be expected. Due to the need for functional outcome, the Abbe and Estlander flaps have decreased in popularity, replaced in large part by the Karapandzic flap.

Bibliography:

1. Papel I et al. Facial Plastic and Reconstructive Surgery. Chapter 51: Lip Reconstruction. Thieme Publishing, New York, NY; 2002; 634-645.
2. Baker SR et al. Local Flaps in Facial Reconstruction. Chapter 19: Reconstruction of the Lip. Mosby Elsevier, Philadelphia, PA; 2007; 475-524.
3. Dolan RW et al. Facial Plastic, Reconstructive, and Trauma Surgery. Chapter 7: Specialized Local Facial Flaps for the Eyelids and Lips. Marcel Dekker, Inc, New York, NY; 2003; 201-232.
4. Pasha R et al. Otolaryngology Head and Neck Surgery: Clinical Reference Guide. Chapter 5: Head and Neck Cancer. Singular, San Diego, CA; 2001; 239-243.
5. Moretti A, et al. Surgical Management of Lip Cancer. Acta Otorhinolaryngol Ital. 2011 February; 31(1): 5–10.
6. Schulte DL, Sherris DA, Kasperbauer JL. The anatomical basis of the Abbé flap. Laryngoscope. 2001 Mar;111(3):382-6.
7. McCarn KE, Park SS. Lip reconstruction. Otolaryngol Clin North Am. 2007 Apr;40(2):361-80.
8. Jeng SF, Kuo YR, Wei FC, Su CY, Chien CY. Total lower lip reconstruction with a composite radial forearm-palmaris longus tendon flap: a clinical series. Plast Reconstr Surg. 2004 Jan;113(1):19-23.
9. Abbé RA. A new plastic operation for the relief of deformity due to double hairlip. Med Rec 1889;53:447.
10. Estlander JA. Eine Methods ans der einen Lippe substanzverluste der anderen zu ersetzen. Arch Klin Chir 1872;14: 622.
11. Karapandzic M. Reconstruction of lip defects by local arterial flaps. Br J Plast Surg 1974;27:93-7.
12. Freedman, A. M., and Hidalgo, D. A. Full-thickness cheek and lip reconstruction with the radial forearm free flap. Ann. Plast. Surg. 25: 287, 1990.
13. Daya M, Nair V. Free radial forearm flap lip reconstruction: a clinical series and case reports of technical refinements. Ann Plast Surg. 2009 Apr;62(4):361-7.