

**TITLE: Recurrent Respiratory Papillomatosis**  
**SOURCE: Grand Rounds Presentation, University of Texas Medical Branch,**  
**Dept. of Otolaryngology**  
**DATE: June 25, 2008**  
**RESIDENT PHYSICIAN: Ryan Ridley, MD**  
**FACULTY PHYSICIAN: Jing Shen, MD**  
**DISCUSSANT: Charles Vaughn, MD, Boston University**  
**SERIES EDITORS: Francis B. Quinn, Jr., MD**

---

*"This material was prepared by resident physicians in partial fulfillment of educational requirements established for the Postgraduate Training Program of the UTMB Department of Otolaryngology/Head and Neck Surgery and was not intended for clinical use in its present form. It was prepared for the purpose of stimulating group discussion in a conference setting. No warranties, either express or implied, are made with respect to its accuracy, completeness, or timeliness. The material does not necessarily reflect the current or past opinions of members of the UTMB faculty and should not be used for purposes of diagnosis or treatment without consulting appropriate literature sources and informed professional opinion."*

---

## **Introduction**

Recurrent respiratory papillomatosis (RRP) is a disease of viral etiology caused by HPV types 6 and 11 which results in exophytic lesions in the airway. There are two distinct forms recognized: juvenile onset (most aggressive) and adult onset (less aggressive). RRP is the most common benign neoplasm of the larynx in children and the second most cause of pediatric hoarseness. Juvenile RRP, the main focus of this discussion, is mostly diagnosed between the ages of 2 and 4 yrs old with a delay of symptom onset at approximately 1 year (Silverberg). Children with RRP are diagnosed before their 5<sup>th</sup> birthday 75% of the time.

Incidence is estimated at 2 per 100,000 in adults and 4 per 100,000 in children which equals over 15,000 surgical procedures totaling in excess of one-hundred million dollars per year for childhood procedures! (Derkey, 1995) Plainly stated, 1,500-2,000 new cases of childhood onset RRP occur in the US each year.

RRP not only involves the larynx but can spread into the entire aerodigestive tract. Children whose RRP was diagnosed at ages < 3 years old have 3.6 times more chance to have > 4 surgeries per year and almost twice as likely to have 2 or > anatomic sites affected than children diagnosed at > 3 years old. (Wiatrak)

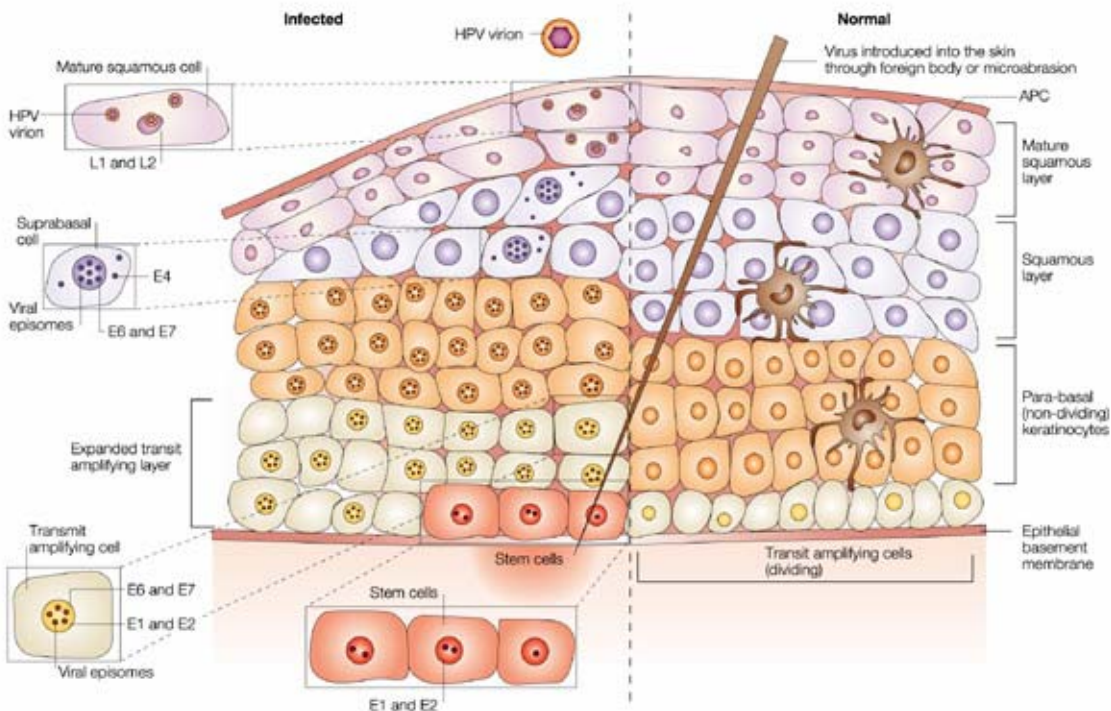
Although RRP is a benign disease it has extremely morbid potential due to its airway involvement and potential for malignant transformation.

## **Etiology**

HPV is the etiological agent in RRP, first discovered in laryngeal papillomas in 1982. HPV is also the cause of the 2<sup>nd</sup> most common female cancer—cervical cancer. It is also associated with anogenital cancers such as anal, penile, vulval, and vaginal carcinomas. (Goon) HPV is a DNA containing, nonenveloped, icosahedral (20 sided) capsid virus with double

stranded DNA ~ 7,900 bp long. HPV types 6 and 11, as stated earlier are the most prevalent types with type 11 having the worst prognosis. Other types of HPV encountered in RRP include types 16 and 18 (highly malignant) and types 31 and 33 (malignant potential more than types 6 and 11, but less than types 16 and 18). It is believed that HPV infects cells by getting set up in the basal layer and releasing its DNA into the cell. This DNA is then transcribed into RNA which is then translated into viral proteins. These proteins will go on to assemble new virions and once they are released, the cycle will continue as these virions infect other cells. The HPV genome is made up of early genes (designated “E”) and late genes (designated “L”) each with unique purposes. Specifically, HPV L1 and L2 genes encode viral capsid proteins while E1 and E2 are responsible for replication and transcription. E4 aids in virus release from infected cells and E6/E7 have transforming abilities. (Goon) Interestingly, following infection of stem cells in the basal layer, the infection can be actively expressed or become latent. To demonstrate this fact, HPV DNA can be detected in normal appearing mucosa in patients with RRP who are in remission. The fact that infection can be latent explains why reactivation and clinical occurrence can take place following years of remission. Host immune response is thought to play a role in the pathogenesis of HPV lesions. Malfunction of cell mediated immune response in patients with juvenile-onset RRP has been demonstrated. Some papillomas may evade immune surveillance and permit a more rapid progression of the disease.

Below is a graphic from Nature Reviews to help illustrate the process of HPV infection as briefly described above:



## Epidemiology

Childhood-onset RRP is most often diagnosed between the ages of 2 and 4 with an estimated incidence of 4 per 100,000 (2 per 100,000 in adults). Briefly, adult RRP peaks between ages of 20-40 yrs and has a slight male predilection. Adult-onset RRP could reflect activation of a virus present at birth or infection acquired in adolescence or adult life. A U.S. survey of practicing otolaryngologists revealed that half the adults with RRP required fewer than 5 procedures over their lifetime as opposed to <25% of children who can share this same statistic. In the U.S., the mean number of surgical procedures per child is estimated at 19.7 with an average of 4.4 procedures per year. (Derkay, 1995)

In terms of distal airway spread and malignant transformation, HPV 11 is more likely to be the culprit than HPV 6. HPV 11 is thought to integrate itself into the host genome and mutate tumor suppressor p53. (Rady)

## Transmission

The exact mode of HPV transmission remains unclear but the most likely method of maternal-fetal HPV transmission is through direct contact via the birth canal. This may explain the clinical observation that most children in whom recurrent respiratory papillomas develop are delivered vaginally to mothers with a history of condylomata. Statistics reveal that not only are children with RRP commonly born vaginally to mothers with a history of condylomata, but they are first-born as well. This fact is significant because primigravid mothers have a large 2<sup>nd</sup> stage of labor and prolonged infant exposure to the virus leads to higher risk of infection. Maternal condylomata during pregnancy was associated with a 200-fold increase in risk of RRP in the child. (Silverberg) In one group of children with juvenile laryngeal papillomatosis, 54% had a maternal history of vulval condyloma at delivery (Hallden) Despite the apparent close association between maternal condylomata and RRP development, few children exposed to genital warts at birth actually develop clinical symptoms. The estimated risk of a child contracting the disease from a mother who has an active condylomatous lesion and delivers vaginally is 1 in 400. What separates this one child from the other 399 is unknown at this point. Although HPV could be recovered in approximately 30% of infants exposed to HPV in the birth canal, only a small fraction of these will exhibit evidence of RRP. Another study found that in 77 mothers with condylomata at delivery, 9 children (11.6%) were later diagnosed with juvenile RRP. (Kjer) It is clear that other factors must be important in determining the development of RRP (i.e. patient immunity, timing, length and volume of virus exposure and local trauma). In contrast, to studies that link childhood RRP to mothers with genital HPV infections, adult-onset RRP may be linked to oral-genital contact. A case control study revealed that adult-onset RRP patients were more likely to have had increased sexual partners and oral sex than their controls. (Kashima)

Since the main theory regarding transmission of RRP in juvenile-onset cases is contact via birth canal, it seems reasonable that cesarean section would eradicate this risk altogether. Unfortunately, there is insufficient evidence to support cesarean section in the prevention of childhood RRP in lieu of the maternal risks associated with this procedure.

## Histology and Lesion Characteristics

RRP lesions occur where ciliary and squamous epithelium are juxtaposed. Ciliated epithelium undergoes squamous metaplasia when exposed to repeated trauma and is replaced with nonciliated epithelium that creates an iatrogenic squamociliary junction. This is probably why RRP is exacerbated in the presence of reflux. In tracheotomized patients, RRP is often found at the stoma and in midthoracic trachea (i.e. iatrogenic squamociliary junction). Histologically, the lesions are pedunculated masses with finger-like projection of nonkeratinized stratified squamous epithelium supported by a core of highly vascularized connective tissue stroma. Grossly, papillomas may be sessile or pedunculated and usually occur in exophytic clusters. They appear pinkish/white in color.

## Clinical Characteristics

RRP has a hallmark triad of progressive hoarseness, stridor, and respiratory distress. Due to the fact that the most common symptoms are related to airway obstruction, many children are misdiagnosed with croup, asthma, or chronic bronchitis. Any child with voice changes, obstructive airway symptoms should get fiberoptic laryngoscopy or direct laryngoscopy to rule out neoplasia with RRP being high on the differential. RRP presenting in the neonatal period is thought to be a negative prognostic factor with a greater likelihood for mortality and need for tracheotomy.

Extralaryngeal spread of respiratory papillomatosis has been identified in 13-30% of children and in 16% of adults with RRP. The most common sites for RRP are as follows:

- -limen vestibuli,
- -nasopharyngeal surface of soft palate
- -midline of laryngeal surface of epiglottis
- -upper and lower margins of ventricle
- -undersurface of vocal folds
- -carina
- -bronchial spurs

The most frequent extralaryngeal sites were (in order of frequency): oral cavity, trachea, and bronchi.

There is controversy as to whether tracheostomy exacerbates distal spread of disease. Certain authors such as Cole *et al* reported that increased tracheal spread occurred in their patients with RRP who received tracheotomy. (Holland) However, in opposition to this, Shapiro *et al* did not believe that placement of tracheotomy contributed to distal spread of disease.

## Patient Assessment/Gathering history

Hoarseness, although a common/benign complaint in children, always indicates some abnormality of structure or function. Important information to gather is:

- Time of symptom onset
- Airway trauma? Previous intubation?
- Characteristics of cry

Voice assessment should involve determination of the quality of voice:

- -low pitched, coarse, fluttering voice suggests subglottic lesion
- -high pitched cracking voice aphonia or breathy voice suggests glottic lesion or subglottic lesion

Other important things to assess:

- age of onset
- rate of progression
- associated infection
- history of trauma or surgery
- presence of respiratory or cardiac distress

Also, it is important to not be fooled by stridor that is present at birth. Although this is most likely laryngomalacia, subglottic stenosis, vocal cord paralysis or vascular ring, you must remember that neonates also can present with papillomatosis. In addition, it is important to review the perinatal period for a history of maternal or paternal condylomata.

#### **Physical exam:**

- Assess respiratory rate and degree of distress first
- Observe for flaring of nasal ala, use of accessory neck/chest muscles
- Cyanosis or air hunger( child may sit with neck hyperextended)
- Be careful in very sick children. Detailed physical exam should be done in the OR, ER, or ICU where equipment for resuscitation, intubation, and tracheotomy can be performed

## **Malignant Transformation**

Malignant transformation of laryngeal or pulmonary lesions is considered rare and is estimated to occur in 1-7% of patients with RRP (Geriens). Typically, malignant transformation occurs in those patients with advanced disease, usually pulmonary extension of RRP, who are subsequently diagnosed with lung carcinoma. This lung carcinoma will have the same virus as benign papillomas in the larynx. This usually occurs during the third or fourth decade of life. As described earlier, the majority of these lesions contain HPV type 11 as opposed to type 6. The reliability of prognostic factors other than age of onset for predicting severity of RRP (including malignant transformation) is undefined. Geriens *et al* demonstrated that the average duration of RRP until malignant transformation lies within a range of approximately 19-35 yrs and approximately 9-21 yrs from the time pulmonary extension is diagnosed.

## Treatments

Surgical debridement is the mainstay of treatment with the aims of maintaining a safe airway and a good voice. The most favored method currently is usage of the powered microdebrider instead of CO<sub>2</sub> laser due to decreased surgical time, less cost and better voice quality, with no increase in pain. (Pasquale)

Existing adjuvant therapy is considered “off-label” usage; however the following medical treatments have been explored thus far:

- **Interferon-**  
Has antiviral, antiproliferative and immunomodulatory effects by binding to membrane receptors and altering cell metabolism. Exact mechanism is unknown. The conclusion is that interferon is neither curative alone nor of any value as adjunctive treatment (Healy)
- **Cidofovir-**  
A cytosine analogue that is active against many DNA viruses. Precise mechanism unknown but thought to induce apoptosis and augment the immune response. Prospective studies have shown intralesional cidofovir to promote regression (partial and complete) of papillomas and decrease frequency of surgical debulking. (Tasca)
- **Antivirals-**  
Namely Ribavirin and acyclovir. Evidence proving efficacy for these is weak/anecdotal. Effect is not directed at HPV but against co-infecting viruses.
- **Indole-3-carbinol-**  
Derived from cruciferous vegetables. Thought to affect papillomas via effect on estrogen metabolism. Prospective study has shown some benefit but evidence of clinical efficacy is equivocal.
- **Mumps vaccine-**  
Unclear mechanism but authors feel that intralesional mumps vaccine promotes induction of remission in children with RRP.
- **Control of GERD-**  
LPR is thought to exacerbate severity of RRP. Prospective study by authors like McKenna Demonstrates improved control of RRP and ometimes remission when GERD is controlled. (McKenna)
- **HspE7-**  
Recombinant fusion protein of Hsp65 of *M. bovis* and E7 protein from HPV 16. Open label study has shown statistically significant decrease in the patient’s annual frequency of surgery and decreased absolute number of surgeries. (Derkay, 2005)

## Conclusion

RRP although rare, is a debilitating disease with grave consequences to the airway if left unnoticed and uncontrolled. Currently great locoregional control is possible through frequent surgical debridement which adjuvant treatment may be able to decrease. At this point, not only must more research be undertaken to find a solution, more research must be performed to

understand more about the problem—the HPV virus. Fortunately, with the advancements currently accomplished, the future looks promising.

## **Discussant: Charles Vaughn, Boston University School of Medicine**

You may recall that BU had a large experience with this disorder, eventually totaling close to 400 patients. It was a biased cohort, almost all referred because of prior treatment failure. Even so, our experience supports your report.

May I add a few comments? First a couple of minor (unscientific) ones:

Regarding infection: "It is clear that other factors must be important in determining the development of RRP (i.e. patient immunity, timing, length and volume of virus exposure and local trauma)." ...At one time I was treating (with the CO2 laser) 4-5 cases/day several days/wk and because a laser impact on a surgical glove caused a more painful burn than that onto skin, I did not wear gloves. I never developed papilloma, etc., nor did any of my family (wife and 4 daughters).

Regarding: "There is controversy as to whether tracheostomy exacerbates distal spread of disease."... Many of our patients arrived with tracheotomy in place and all of these had distal spread. Others, even those with massive RRP, but without trach on arrival, were kept trach free by diligent RX (surgical debridement) and none developed distal spread.

Note the logical discord in these two quotes from your article:

1. "Since the main theory regarding transmission of RRP in juvenile- onset cases is contact via birth canal, it seems reasonable that cesarean section would eradicate this risk altogether..." ("altho there is no evidence to support this").

2. "...you must remember that neonates also can present with papillomatosis." I have provided malpractice defense based on #2.

Finally, the purpose of this discourse:

Regarding: "Surgical debridement is the mainstay of treatment with the aims of maintaining a safe airway and a good voice."

"In the U.S., the mean number of surgical procedures per child is estimated at 19.7 with an average of 4.4 procedures per year. (Derkay, 1995)"

I wish that your article had defined more clearly the limits of "Surgical debridement is the mainstay of treatment with the aims of maintaining a safe airway and a good voice." It lacks discussion of complications from the "average of 19.7 surgical procedures"- when performed for cure. In those referred to us we saw far too many glottic cripples when the surgical purpose had been, as it commonly was, and still often is: "cure", i.e., elimination of all evidence of papilloma by removal/destruction of its mucosa base. In such circumstance, scar (and vocal and respiratory pathology) is inevitable.

As your article states, virus can be recovered from any location at any time, despite all known treatment. There is no known cure. Thus, surgical treatment purpose can only be relief of symptoms, not cure.

One should remove only papilloma that debilitate, sparing all mucosa. Remission will occur when the fates, not the physician, dictate.

And be not surprised at recurrence- at any time. (Recently I received a phone call from a young female, now a Resident in our specialty. She gave her name and inquired if I remembered her, which, of course, I did. At age 4-5 I had treated her for massive RRP, attempting only to maintain an airway sans trach. Eventually remission occurred, leaving a normal larynx. Why then did I detect some hoarseness when she spoke?

She now, in her late twenties, had recurrence!!)

Otherwise the article was well written and I enjoyed reading it.

## Bibliography

Soma MA, Albert DM. Cidofovir: to use or not to use? *Curr Opin Otolaryngol Head Neck Surg*. 2008 Feb;16(1):86-90. Review.

Goon P, Sonnex C, Jani P, Stanley M, Sudhoff H. Recurrent respiratory papillomatosis: an overview of current thinking and treatment. *Eur Arch Otorhinolaryngol*. 2008 Feb;265(2):147-151

Chadha NK, James AL. Antiviral agents for the treatment of recurrent respiratory papillomatosis: a systematic review of the English-language literature. *Otolaryngol Head Neck Surg*. 2007 Jun;136(6):863-9. Review.

Zacharisen MC, Conley SF. Recurrent respiratory papillomatosis in children: masquerader of common respiratory diseases. *Pediatrics*. 2006 Nov;118(5):1925-31.

Tasca RA, Clarke RW. Recurrent respiratory papillomatosis. *Arch Dis Child*. 2006 Aug;91(8):689-91. Review.

McKenna M, Brodsky L. Extraesophageal acid reflux and recurrent respiratory papilloma in children. *Int J Pediatr Otorhinolaryngol*. 2005 May;69(5):597-605.

Rosen CA, Bryson PC. Indole-3-carbinol for recurrent respiratory papillomatosis: long-term results. *J Voice*. 2004 Jun;18(2):248-53.

Pasquale K, Wiatrak B, Woolley A, Lewis L. Microdebrider versus CO2 laser removal of recurrent respiratory papillomas: a prospective analysis. *Laryngoscope*. 2003 Jan;113(1):139-43.

Pashley, Nigel R.T. Can Mumps Vaccine Induce Remission in Recurrent Respiratory Papilloma? *Arch Otolaryngol Head Neck Surg*. 2002; 128: 783-786

Silverberg MJ, Thorsen P, Lindeberg H, et al. Clinical course of RRP in Danish children. *Arch Otolaryngol Head Neck Surg* 2004; 130:711-7116.

Derkay CS. Task force on recurrent respiratory papillomas. *Arch Otolaryngol Head Neck Surg* 1995;121:1386-1391.

Wiatrak BJ, Wiatrak DW, Broker TR, Lewis L. RRP: a longitudinal study comparing severity associated with HPV types 6 and 11 and other risk factors in a large pediatric population. *Laryngoscope* 2004;114:1-23

Rady PL, Schnadig VJ, Weiss RL, Hughes TK, Tying SK (1998) Malignant transformation of recurrent respiratory papillomatosis associated with integrated human papillomavirus type 11 DNA and mutation of p53. *Laryngoscope* 108:735-740

Silverberg MJ, Thorsen P, Lindeberg H, Grant LA, Shah KV (2003) Condyloma in pregnancy is strongly predictive of juvenile onset recurrent respiratory papillomatosis. *Obstet Gynecol* 101:645–652

Hallden C, Majmudar B (1986) The relationship between juvenile laryngeal papillomatosis and maternal condylomata acuminata. *J Reprod Med* 31:804–807

Kashima HK, Shah F, Lyles A, Glackin R, Muhammad N, Turner L, Van Zandt S, Whitt S, Shah K (1992) A comparison of risk factors in juvenile-onset and adult-onset recurrent respiratory papillomatosis. *Laryngoscope* 102:9–13

Holland BW, Koufman JA, Postma GN, McGuirt WF Jr. Laryngopharyngeal reflux and laryngeal web formation in patients with pediatric recurrent respiratory papillomas. *Laryngoscope* 2002;112:1926–1929.

Healy GB, *et al.* Treatment of recurrent respiratory papillomatosis with human leukocyte interferon. Results of a multicenter randomized clinical study. *N Engl J Med* 1988; 319: 401-407.

Derkay, Craig S. *et al.* HspE7 Treatment of Pediatric Recurrent Respiratory Papillomatosis: Final Results of an Open-Label Trial. *Ann Otol Rhinol Laryngol* 2005; 114: 730-7

Kjer JJ, Eldon K, Dreisler A (1988) Maternal condylomata and juvenile laryngeal papillomas in their children. *Zentralbl Gynakol* 110:107–110

Gerien, *et al.* Incidence, age at onset, and potential reasons of malignant transformation in recurrent respiratory papillomatosis patients: 20 years experience. *Otolaryngol Head Neck Surg* 2005; 132: 392-394.