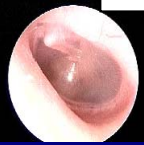
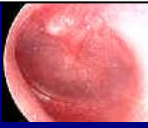
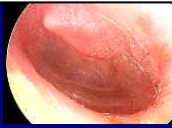SEVERITY GRADING -TYMPANIC MEMBRANE



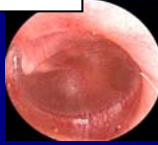0: Normal, or effusion without erythema



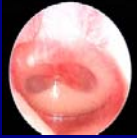
1: Erythema only, no effusion



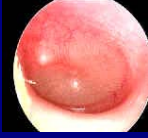2: Erythema, air/fluid level, clear fluid



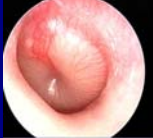3: Erythema, complete effusion, no opacification



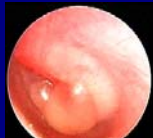
4: Erythema, opacification with air-fluid level or air bubble(s), no bulging



5: Erythema, complete effusion, opacification and no bulging



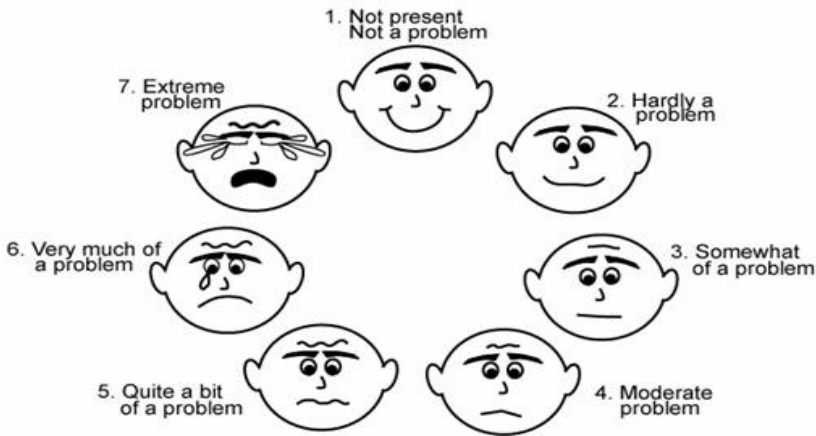
6: Erythema, bulging rounded doughnut appearance of the tympanic membrane



7: Erythema, bulging, complete effusion and opacification with bulla formation

FOLD HERE,
CUT TO SIZE, AND
LAMINATE

Which face describes your child's symptoms during the past 24 hours?



© David P. McCormick, M.D., 2005