

Foreign Body Aspiration

Ki-Hong Kevin Ho, MD

Faculty Advisor: Harold Pine, MD

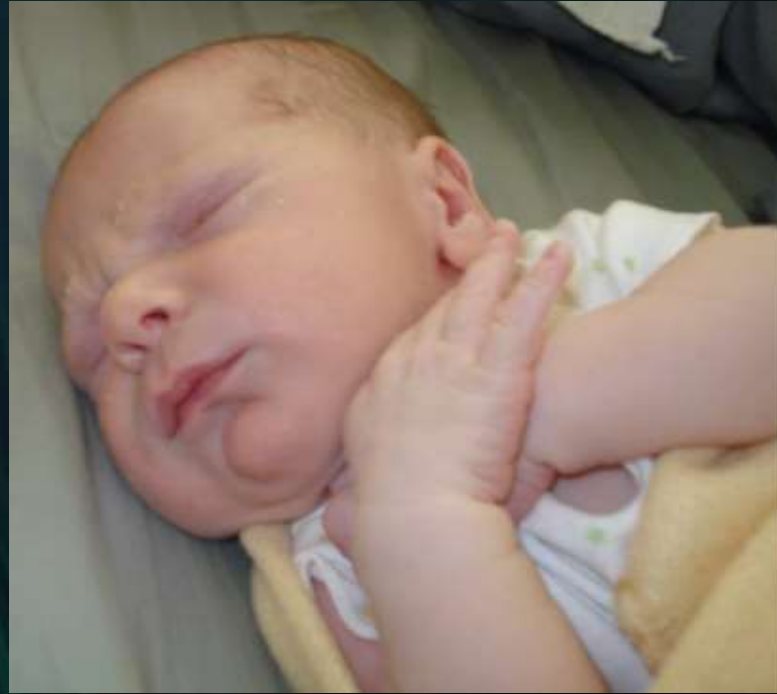The University of Texas Medical Branch

Department of Otolaryngology

Grand Rounds Presentation

February 25, 2009

Foreign Body Aspiration



UTMB Department of Otolaryngology

K. Kevin Ho, MD

Harold Pine, MD

Epidemiology

- Major cause of accidental death
- 17,000 ER visits (aspiration + ingestion) in 2000
- 1,500 die each year due to FB aspiration
- Majority < age 3
- Male > Female

Aspiration in young children

- Lack of molar teeth
- Poorer mastication
- Tendency to put things in mouth
- Playing with things in mouth
- Immature protective laryngeal reflexes

Foreign body

Foreign body	Number of patients	%
Watermelon seeds	593	39.7
Peanut	203	13.6
Sunflower seeds	145	9.7
Bean	100	6.7
Nuts	52	3.5
Other organic FBs	249	16.7
Inorganic FBs	151	10.1
Total	1493	100

More than 200 stores in 31 states pulled tubs of Mini Fruity Gels off shelves because of safety concerns.



Cover story

By LARRY GREENE & JOHN FILLMORE

Gel candies 'like rubber stoppers' linked to deaths

Consumer calls prompted action at one major chain

By Gary Strauss
USA TODAY

Michelle Enzile's life essentially ended April 10, 1999, when she fell into a coma after allegedly swallowing a popular gel-like candy made by Taiwan-based Sheng Hsiang Jen Foods.

Unable to breathe for nearly 30 minutes after collapsing in her San Jose, Calif., home, the fourth-grader sustained brain damage from which there was virtually no chance of recovery, says her physician, Elaine Pico. Three weeks ago on July 30, Gil and Yvonne Enzile awoke to find that their daughter, 12 years old by then, had died.

"Even though everyone told us she would never recover, we still had high hopes that she'd come back to us as a normal kid," says Gil Enzile, a 48-year-



Little girl lost: Michelle Enzile went into a coma on April 10, 1999. She died July 30 of this year.

old engineer at semiconductor equipment maker Applied Materials. "All this over a piece of candy. It's like

bringing a gun into your house and not knowing when it will go off. We're still in shock."

Long popular in Asian countries, the gel candy has been removed in recent days from store shelves of three major U.S. retail chains — Safeway, Albertson's and Costco — in at least 31 states, Mexico and the United Kingdom.

The candies are marketed under a

► Deaths prompt retailers to remove gel candy from shelves, IA

variety of brand names, including Fruit Poppers, Jelly 'n'um and Mini Fruity Gels. The candies also have been linked to last year's choking deaths of 3-year-old Devin Joncich of Morgan Hill, Calif., and Arturo Lopez, a Seattle 2-year-old. A Canadian girl, whose name has not been made public, also died last year.

The jellies, which until last year were sold primarily in small Asian and

See COVER STORY next page ►

Symptoms and Physical findings

- Cough
- Dyspnea
- Wheezing
- Stridor
- Cyanosis
- Decreased breath sounds
- Tachypnea
- Rhonchi
- Somnolence

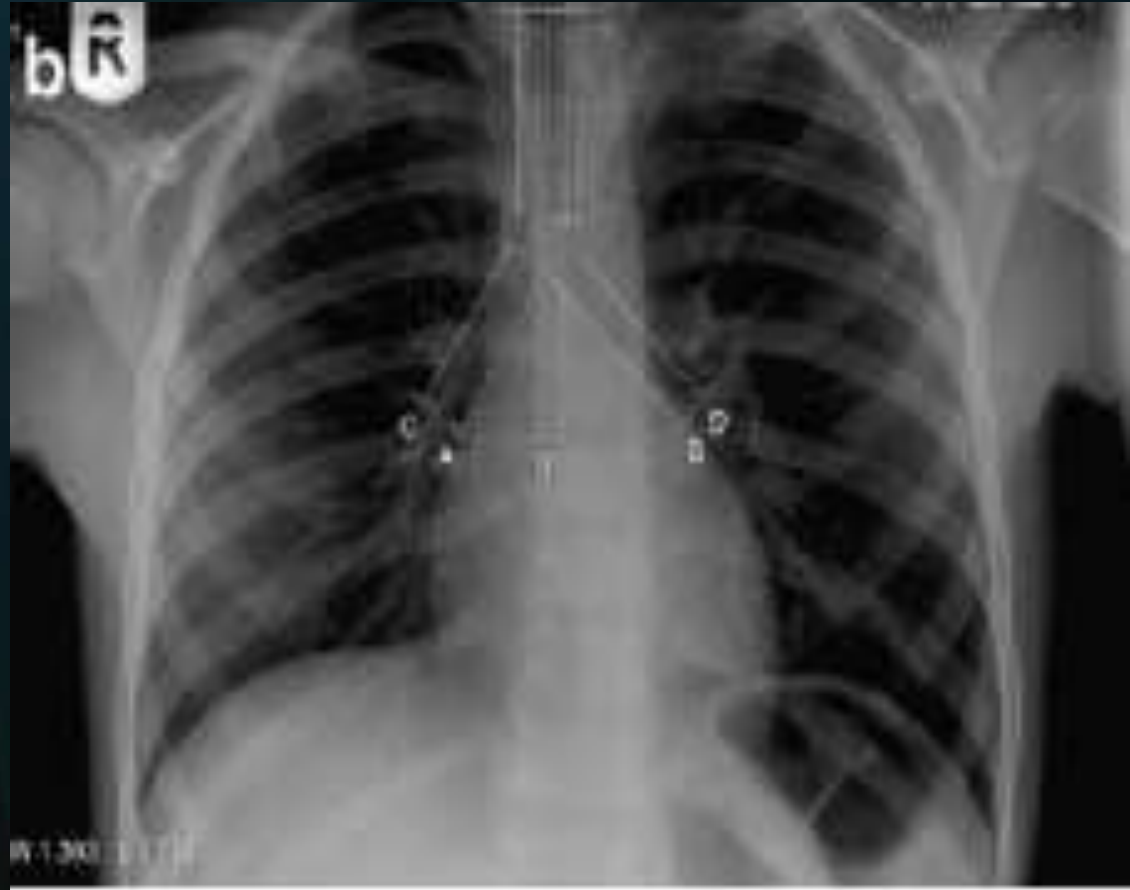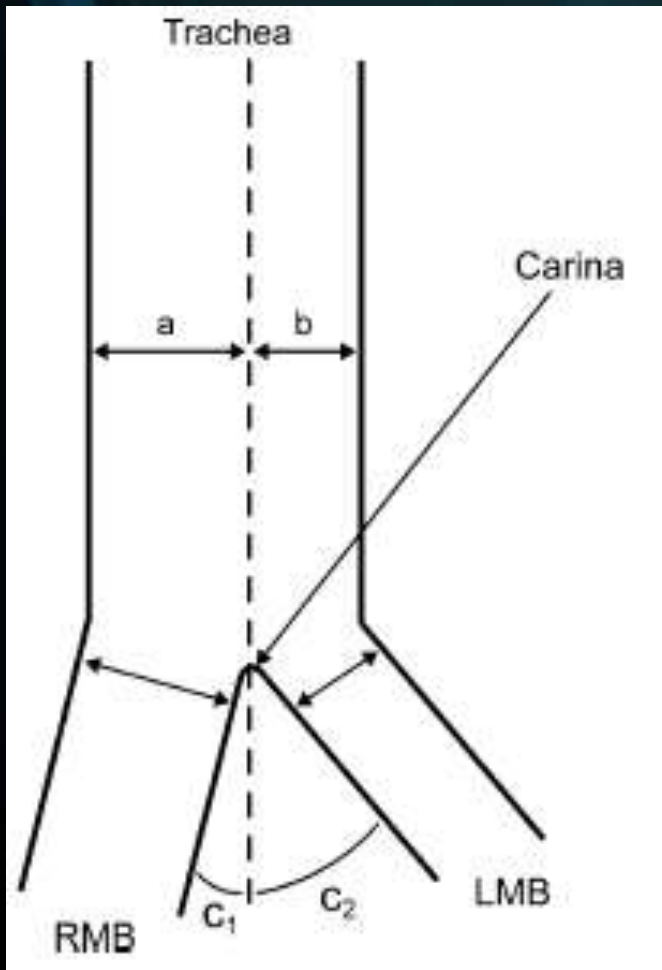
Symptom	Number of patients	%
Sudden onset of coughing	1266	67.1
Dyspnea	910	48.2
Respiratory distress	521	27.6
Cyanosis	196	10.4
Other	130	6.9

Age Difference



Distribution of FB in airway

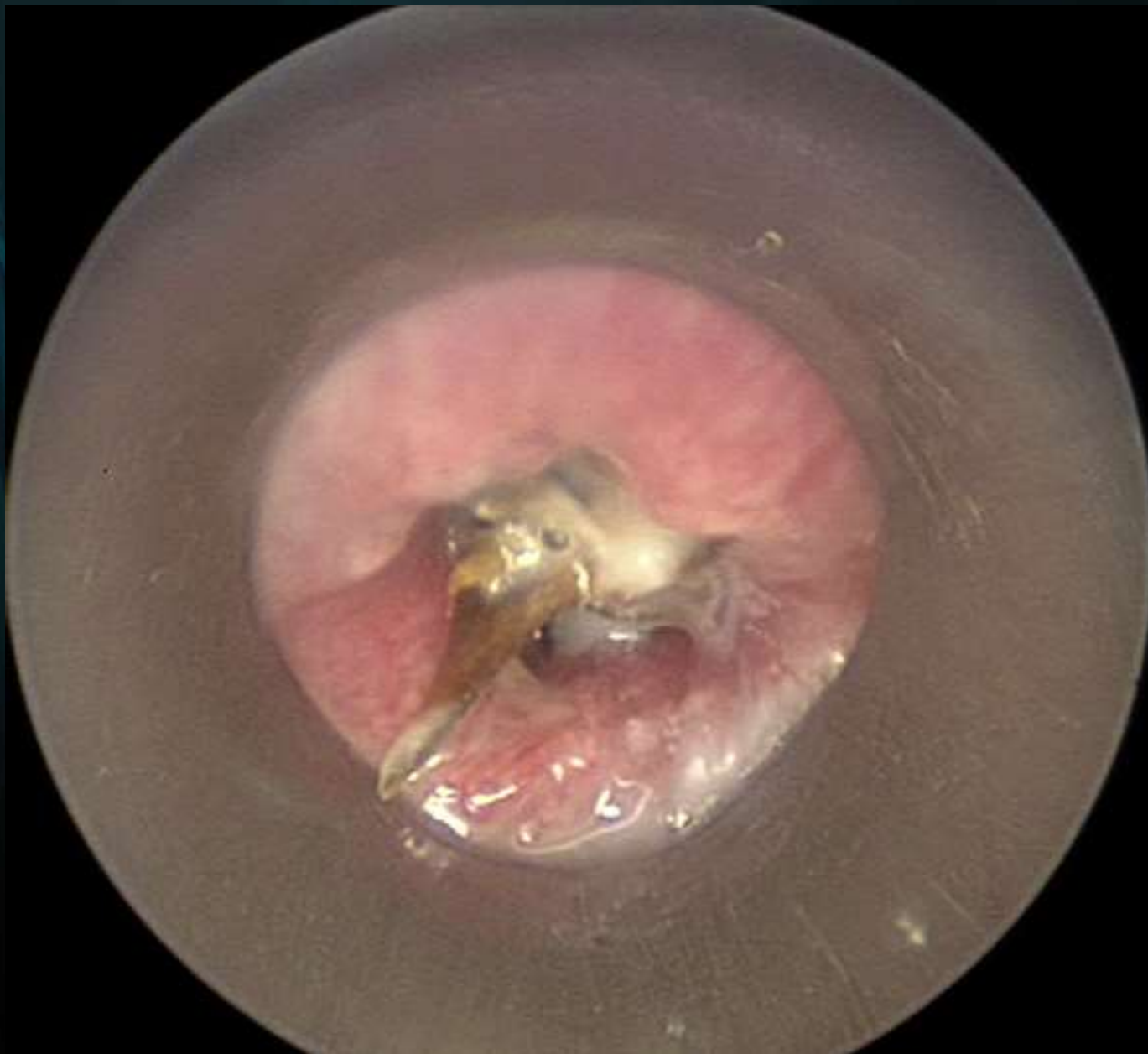
- 70% Right main bronchus in adults
- Higher variability in young children
 - Head/ body position
 - Supine/ Prone position
- Carina usually positioned left of midline ;
Right of midline in 34 % children (Tahir N 2008)



Tahir N et al. 2009.

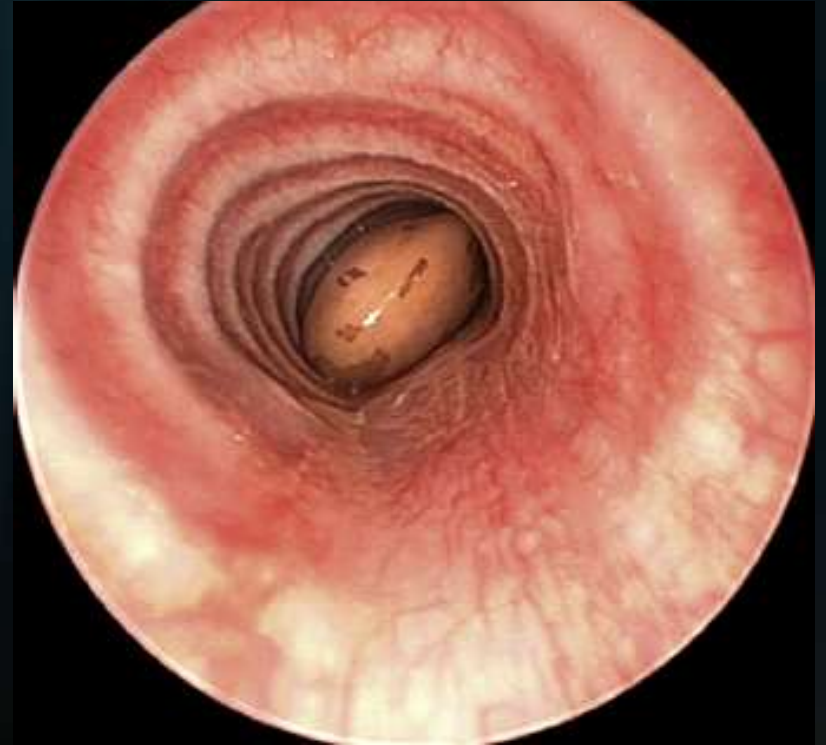Complications

- Mortality after bronchoscopy < 1%
- Bronchiectasis
- Pneumonia / bronchitis
- Subcutaneous Emphysema
- Pneumothorax / pneumomediastinum
- Granulation tissue and hemorrhage
- Cartilage destruction
- Airway compromise
- Death



Diagnosis

- History
- Physical Exam
- Radiography



History of choking

- Highly sensitive ($> 90\%$) for aspiration
- Specificity: 45 – 76%
- Classic history:
 - Choking episode followed by coughing spells

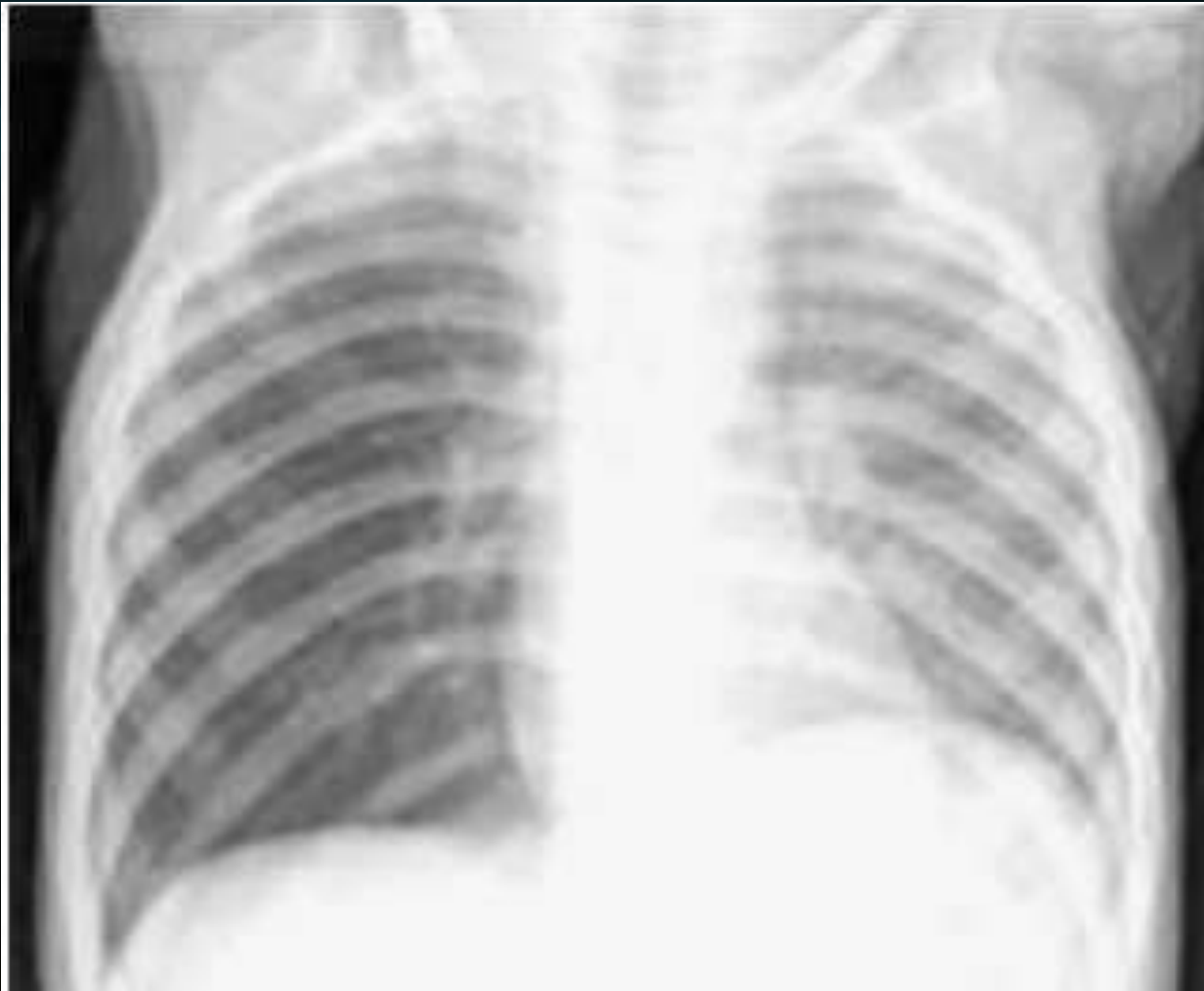Physical Exam

- Sensitivity: 24-86 %
- Specificity: 12-64 %
- Decreased unilateral breath sound
- Unilateral Wheezing
- Stridor

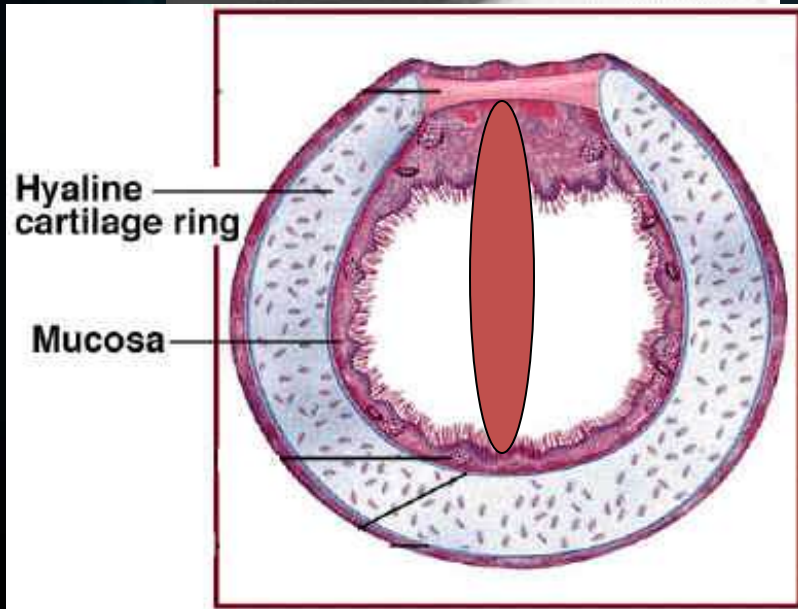
Chest x-ray

- Normal in 20- 40 % of cases
- Most are radiolucent (food origin)
- Inspiratory/ expiratory film
- Air-trapping on expiration
- Atelectasis
- Infiltration
- Consolidation

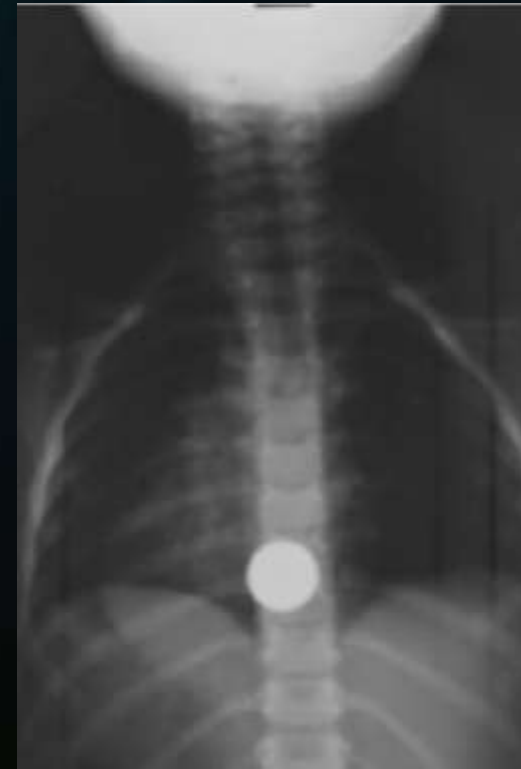Hyperinflation of Right lung



Coin(s) in esophagus

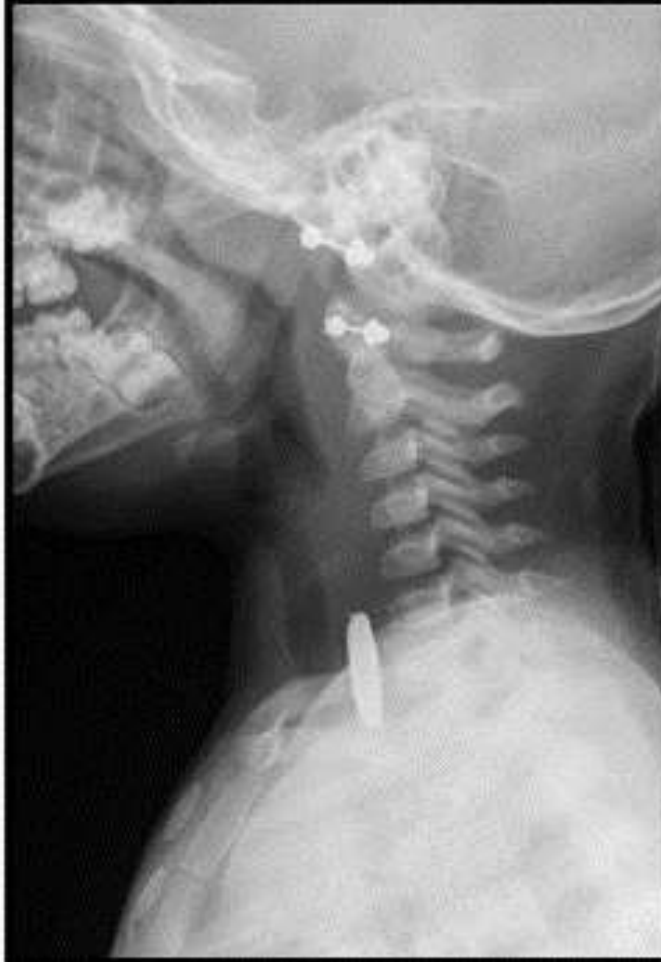
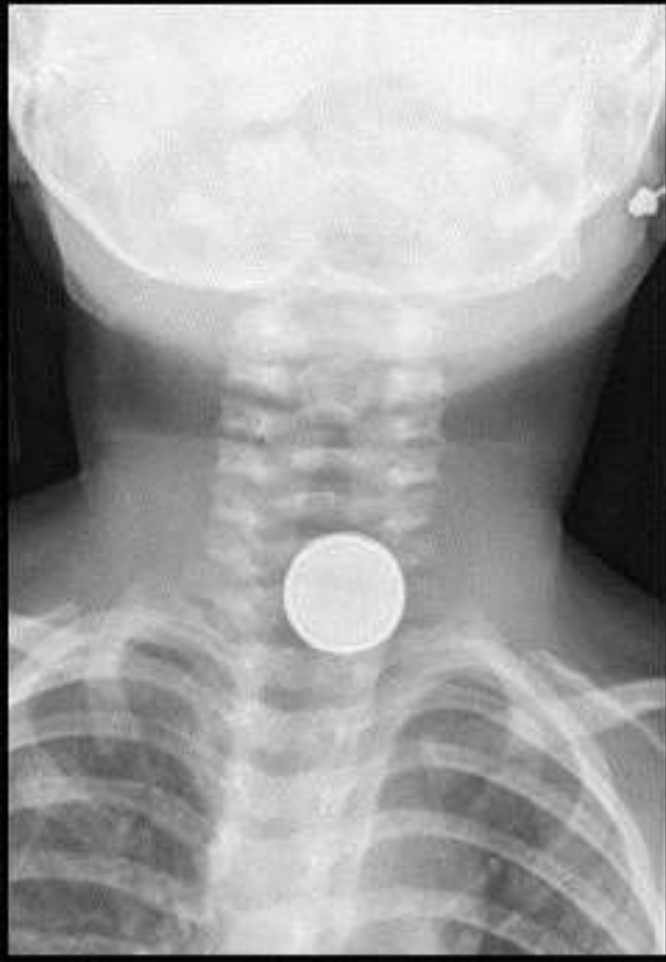
Sagittal orientation on lateral

















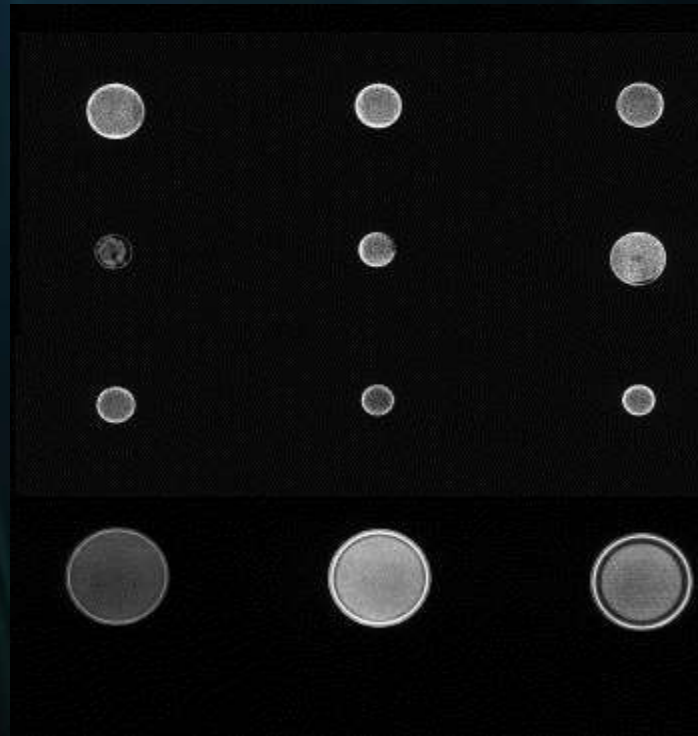
Coronal orientation on PA

Double lumen sign



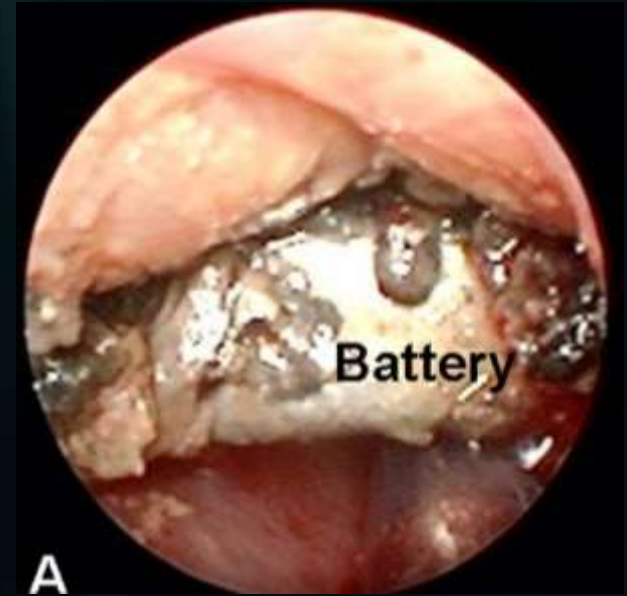
Batteries

L1154	Panasonic SP391	Panasonic SP317
		
Maxell 386	Maxell 394	Maxell 371
		
Hearing Aid Battery	Hearing Aid Battery	Hearing Aid Battery
		
Maxell 362	Maxell 321	Maxell SR626W
		
Sony Lithium	GP Lithium CR2032	GP CR2025
		



Battery

- True emergency
- Double lumen sign
- Leakage of battery contents
- Toxic effect
- Pressure necrosis
- Electrolytic reaction and mucosal burn



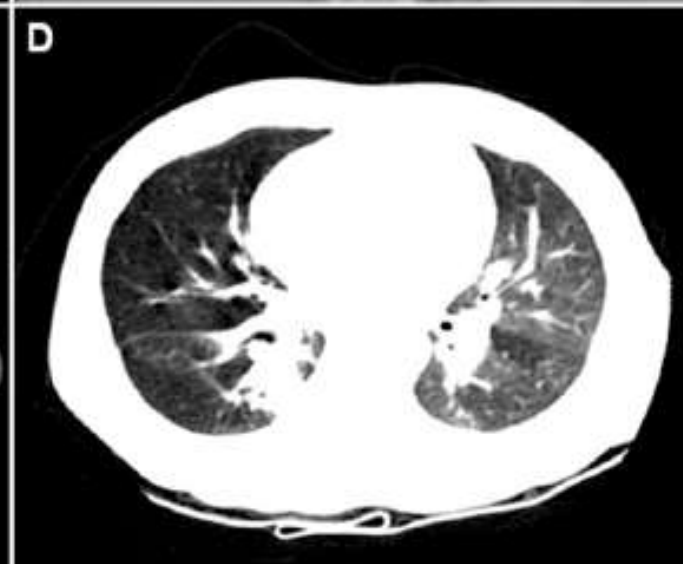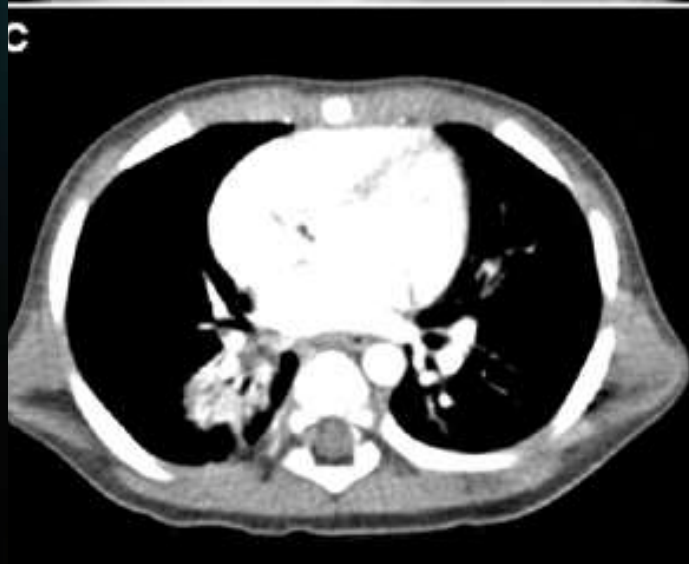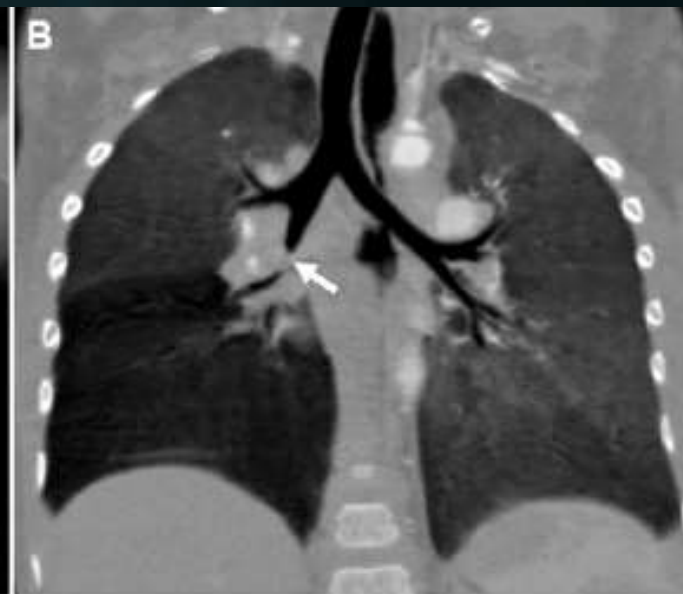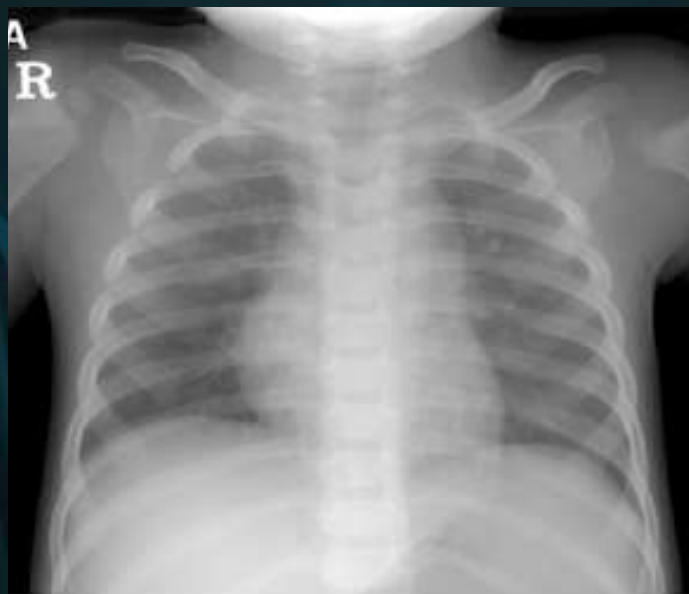Fluoroscopy

- Normal in 53 % of FB patients (Even L 2005)
- Sensitivity: 47%
- Specificity: 95%
- Mediastinal shift
- Paradoxical movement of the diaphragm

CT scan

Diagnostic results of spiral CT	%
Sensitivity	100
Specificity	60.7
Accuracy	94.1
Positive predictive value	93.3
Negative predictive value	100

- Hong SJ 2007
- Retrospective
- 42 patients
- Can visualize radiolucent FBs



Rule of thumb

- Perform bronchoscopy if another one of the following is positive:
 - History
 - PE
 - Radiography
- Bronchoscopic evaluation is warranted on the basis of a positive history alone

Table 1
Sensitivity and specificity of diagnostic tools for AFB diagnosis

Study [Ref.]	N	History	
		Sensitivity (%)	Specificity (%)
Ciftci et al, 2003 [4]	663	91	46
Zerella et al, 1998 [13] ^a	293	86	82
Hoeve et al, 1993 [8]	115	81	33
Barrios et al, 1997 [2]	100	97	63
Metrangelo et al, 1999 [6]	87	96	76
Evan et al, 2005 [5]	98	91	45

Physical examination

Radiography

Physical examination		Radiography	
Sensitivity (%)	Specificity (%)	Sensitivity (%)	Specificity (%)
86	26	88	30
24	64	49	n/a
78	37	82	44
n/a	n/a	85	9
84	12	70	63
80	60	68	71

Medical management

- The role of beta-2 agonist remains unclear
- Alleviation of discomfort
- Expelling foreign body could be life threatening
- Not a replacement for bronchoscopy

Age-appropriate Bronchoscope

BRONCHOSCOPE

2.5 = 4 mm (Premie-Neo)

3 = 5 mm (0-6 months)

3.5 = 5.7 mm (6-18 months)

4 = 7.1 mm (18-36 months)

5 = 8 mm (3-8 years)

6 = 8 mm+ (>8 years)

Bronchoscopes

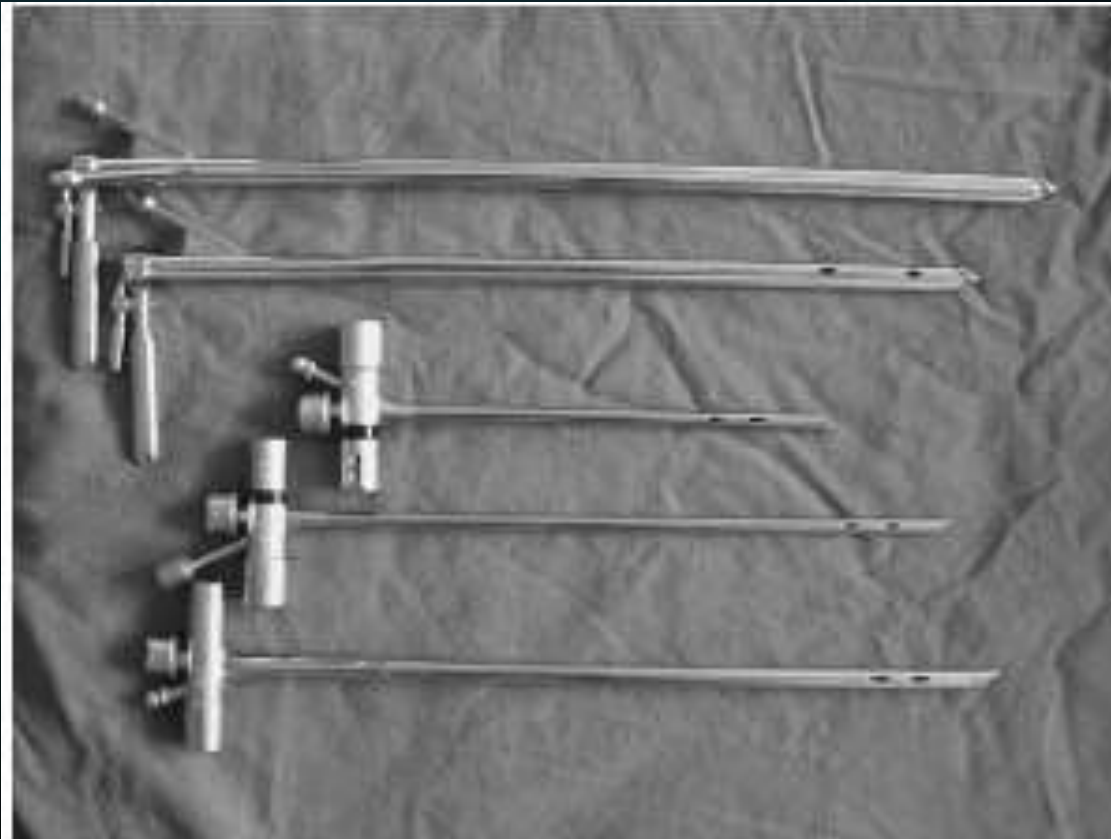
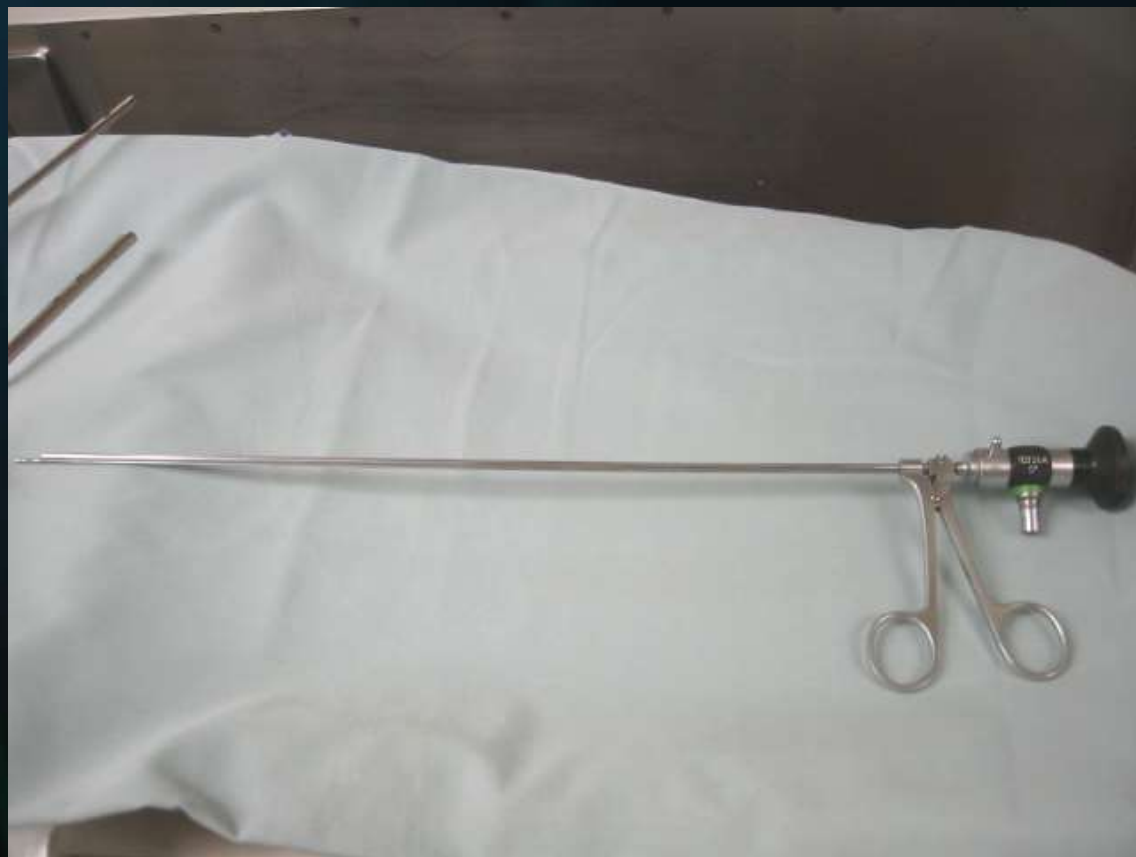

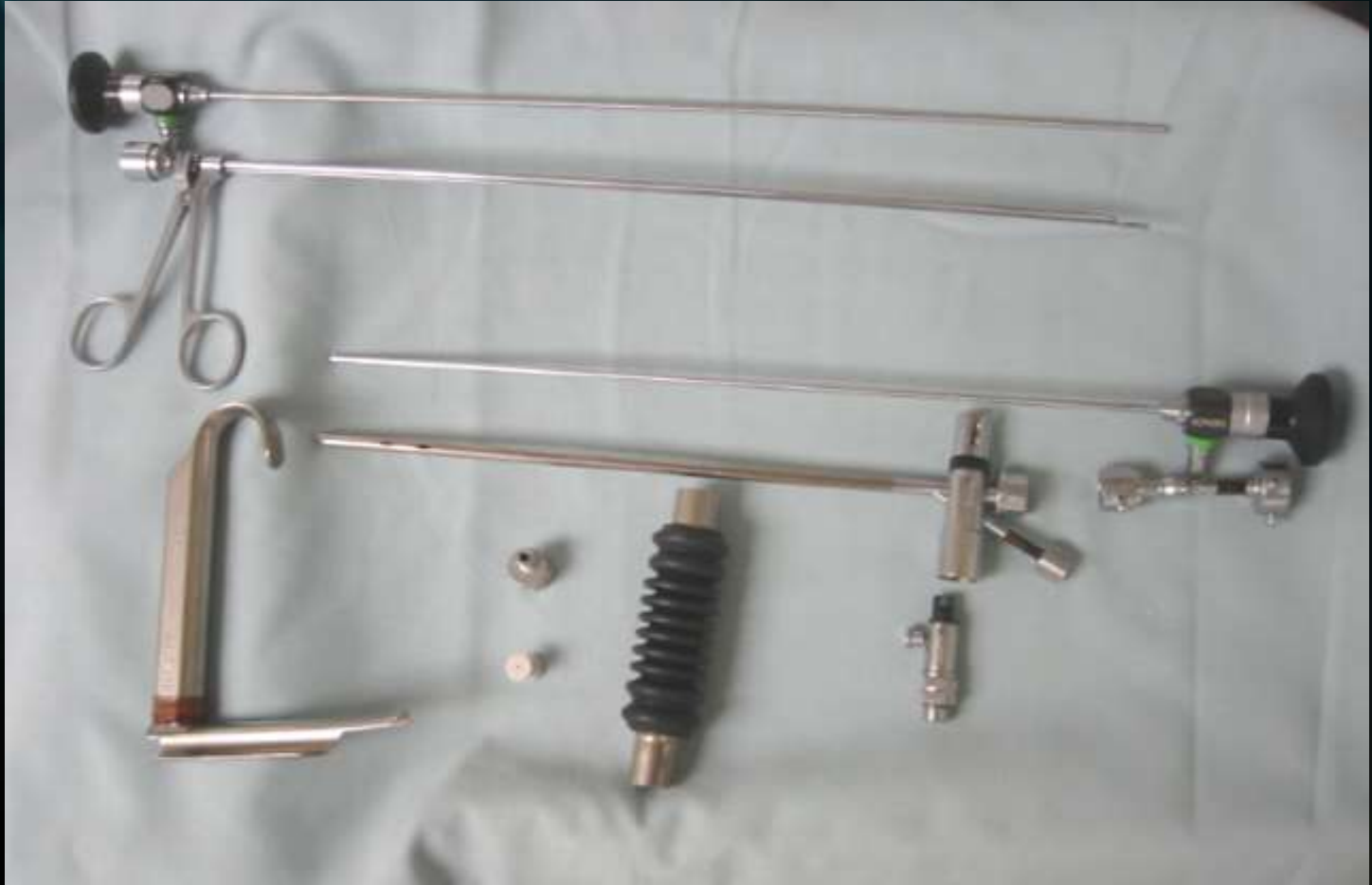Fig. 2 Comparison of two types of pediatric bronchoscopes.





Optical forceps

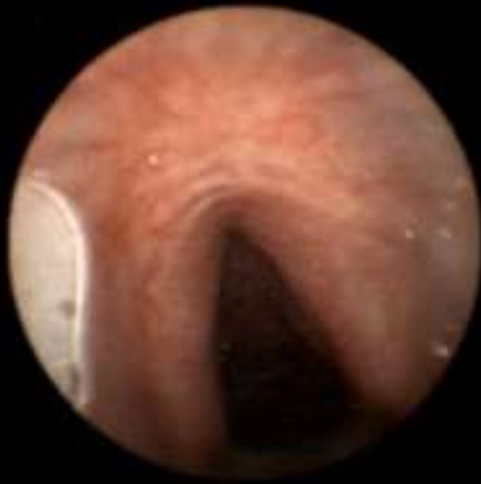



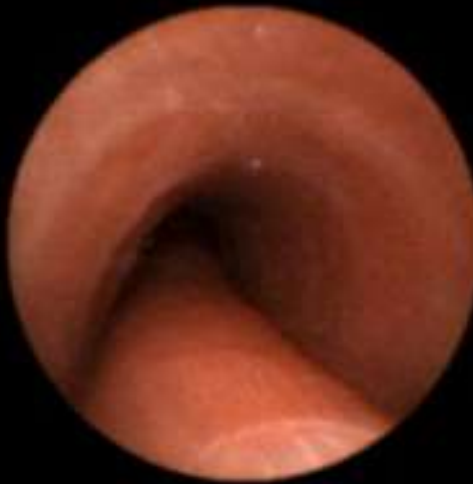Anesthesia

- Availability of experienced Pediatric anesthesiology team
- Daytime vs. night team
- If unstable, securing airway always a priority over fasting guidelines
- Pulse oximetry
- Spray cords with 2% topical lidocaine to avoid laryngeal spasm
- Ventilation via bronchoscope

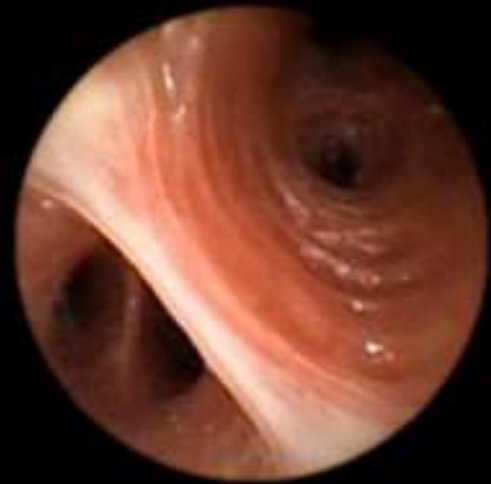Roth net retrieval device



A



B



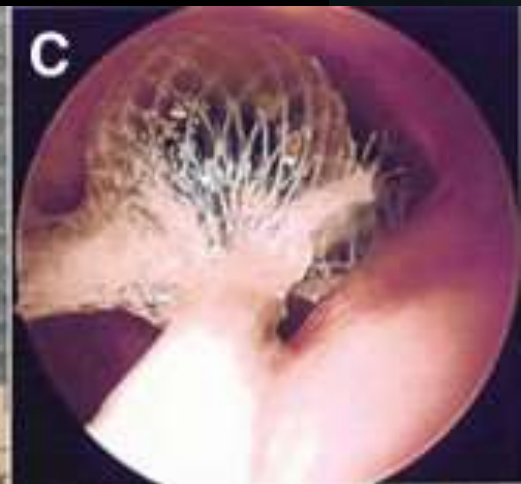
C



A



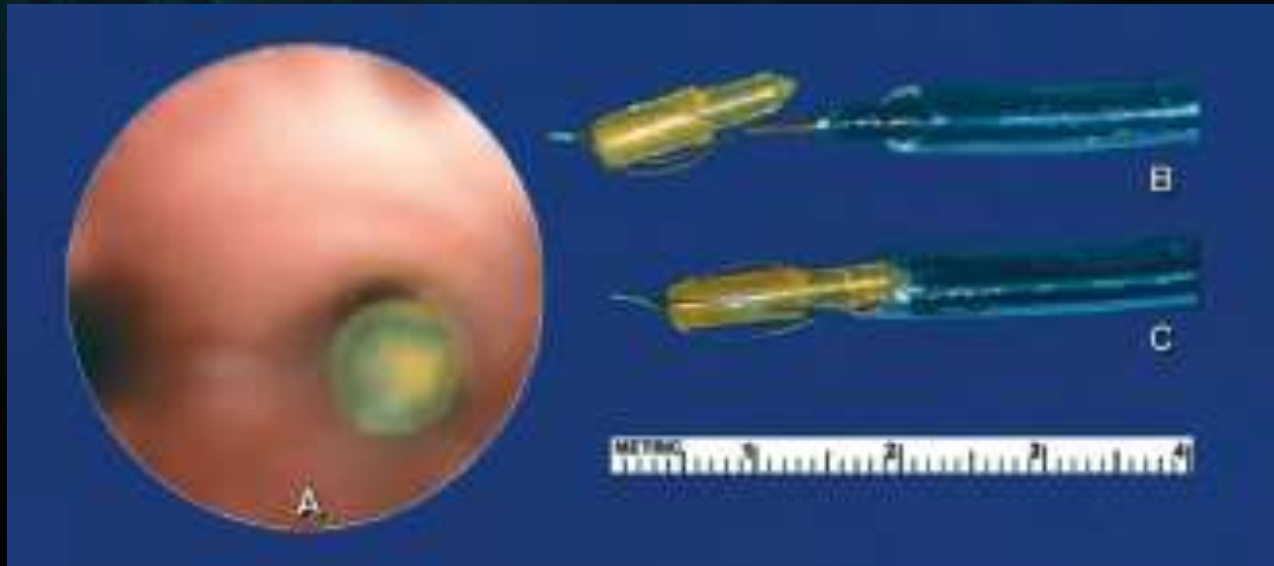
B



C

Fiberoptic bronchoscopy

- Useful when FB migrates to distal bronchi
- Introduced via endotracheal tube or LMA



Role of Tracheotomy

- Incidence 0.5 -3 %
- Large FB in subglottic or proximal trachea
- Concomitant tracheotomy could be performed if FB too big or sharp to pass through glottic area
- Significant laryngeal edema

Postoperative Care

- Admission / observation
- Clear liquid diet
- Chest x-ray
- Chest physiotherapy
- Antibiotics
 - In cases of delayed diagnosis

Summary

- A positive history of choking event followed by coughing is an indication for bronchoscopic evaluation
- Radiographic evaluation is helpful in localization and identification of foreign body.
- Battery aspiration warrants emergent bronchoscopy
- Knowledge of age-appropriate instrument and communication with surgical team are paramount in the management of foreign body aspiration



Thank You



Chevalier Jackson, MD



Errors to Avoid in Suspected Foreign Body Cases

- Do not reach for the foreign body with the fingers.

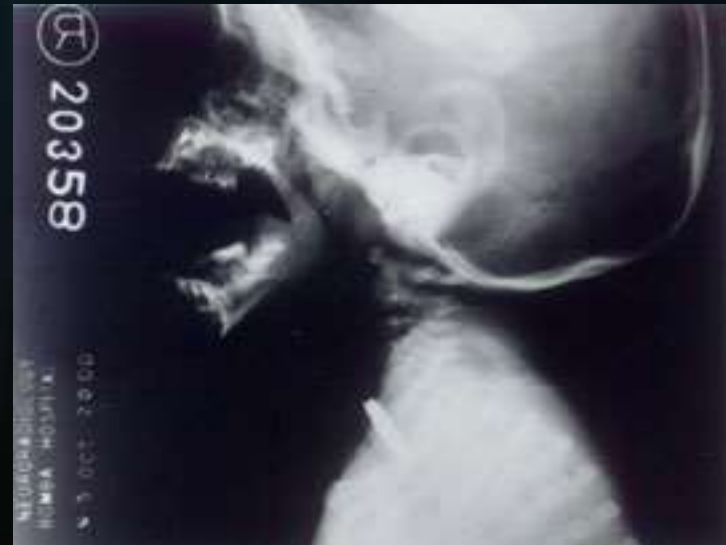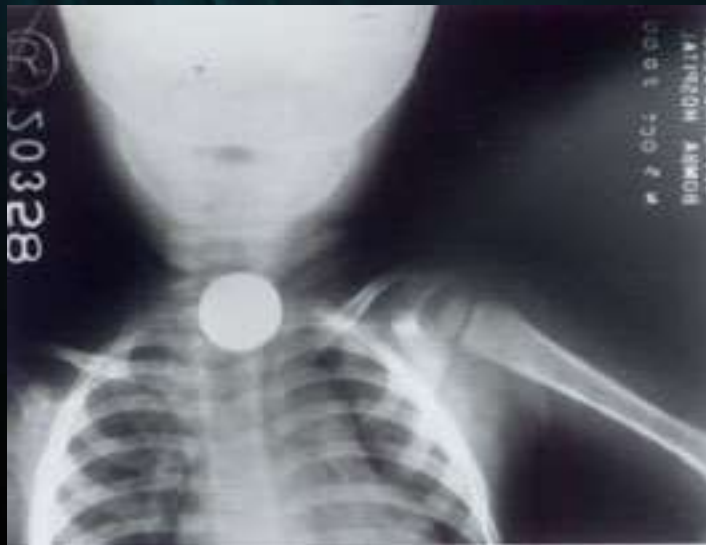Errors to Avoid in Suspected Foreign Body Cases

- Do not hold up the patient by the heels.



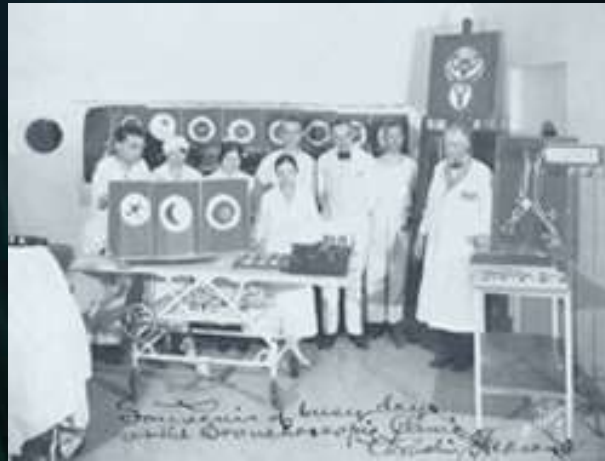Errors to Avoid in Suspected Foreign Body Cases

- Do not fail to have a roentgenogram made.



Errors to Avoid in Suspected Foreign Body Cases

- Do not fail to search endoscopically for a foreign body in all cases of doubt.



Errors to Avoid in Suspected Foreign Body Cases

- Do not pass blindly an esophageal bougie or other instrument.



Errors to Avoid in Suspected Foreign Body Cases

- Do not tell the patient he has no foreign body until after X-Ray examination, physical examination, indirect examination and endoscopy have all proven negative.

The following aphorisms afford food for thought.

- Educate your eye and your fingers.

The following aphorisms afford food for thought.

- Be sure you are right, but not too sure.

The following aphorisms afford food for thought.

- Follow your judgment, never your impulse.

The following aphorisms afford food for thought.

- Cry over spilled milk enough to memorize how you spilled it.

The following aphorisms afford food for thought.

- Let your left hand know what your right hand does and how to do it.



The following aphorisms afford food for thought.

- Nature helps but she is no more interested in the survival of your patient than in the survival of the attacking pathogenic bacteria.