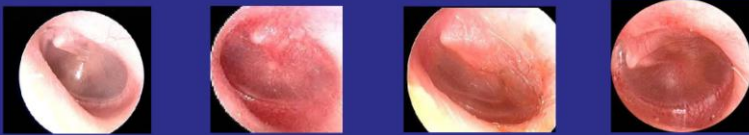


**SEVERITY GRADING - TYMPANIC MEMBRANE**

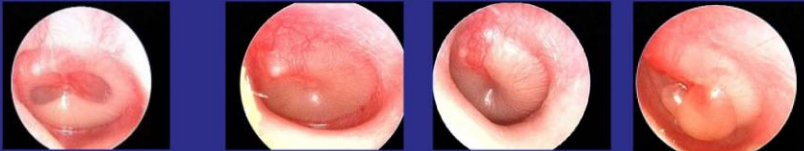
**0 – 3: NOT ACUTE OTITIS MEDIA**



0: Normal, or effusion without erythema  
 1: Erythema only, no effusion  
 2: Erythema, air/fluid level, clear fluid  
 3: Erythema, complete effusion, no opacification

**4 - 5 ? MILD BULGING  
 ? ACUTE OTITIS MEDIA ?**

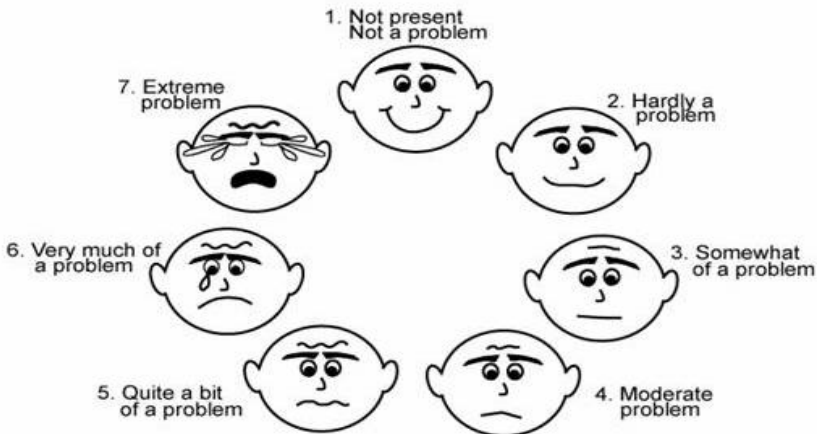
**6 – 7 ACUTE OTITIS MEDIA**



4: Erythema, opacification air fluid level or air bubble(s), mild bulging  
 5: Erythema, complete effusion, opacification, and mild bulging  
 6: Erythema, bulging rounded doughnut appearance of the tympanic membrane  
 7: Erythema, bulging, complete effusion, opacification, bulla

FOLD HERE,  
 CUT TO SIZE, AND  
 LAMINATE

**Which face describes your child's symptoms during the past 24 hours?**



© David P. McCormick, M.D., 2005